



Laparo-endoscopic single-site radical prostatectomy: Feasibility and technique

Amin S. Herati, Mohamed A. Atalla, Sylvia Montag, Sero Andonian, Louis R. Kavoussi, Lee Richstone & Ahmed R. El-Nahas

To cite this article: Amin S. Herati, Mohamed A. Atalla, Sylvia Montag, Sero Andonian, Louis R. Kavoussi, Lee Richstone & Ahmed R. El-Nahas (2011) Laparo-endoscopic single-site radical prostatectomy: Feasibility and technique, Arab Journal of Urology, 9:1, 73-77, DOI: [10.1016/j.aju.2011.03.017](https://doi.org/10.1016/j.aju.2011.03.017)

To link to this article: <https://doi.org/10.1016/j.aju.2011.03.017>



© 2011 Arab Association of Urology



Published online: 05 Apr 2019.



Submit your article to this journal [↗](#)



Article views: 225



View related articles [↗](#)



Arab Journal of Urology
(Official Journal of the Arab Association of Urology)

www.sciencedirect.com



POINT OF TECHNIQUE

Laparo-endoscopic single-site radical prostatectomy: Feasibility and technique

**Amin S. Herati, Mohamed A. Atalla, Sylvia Montag, Sero Andonian,
Louis R. Kavoussi, Lee Richstone ***

*The Smith Institute for Urology, Hofstra University School of Medicine, The North Shore – LIJ Health System,
New Hyde Park, NY, USA*

Received 22 February 2011, Accepted 18 March 2011
Available online 6 May 2011

KEYWORDS

Laparoscopy;
Single-port;
Single-site;
Surgery;
Radical prostatectomy

ABBREVIATIONS

LESS, laparo-endoscopic
single-site surgery; RALP,
robotic-assisted laparoscopic
RP; NOTES, natural orifice
transluminal endoscopic
surgery; RP, radical prosta-
tectomy; VAS, visual analog
scale

Abstract Background: As laparoscopy becomes a standard approach in many urological procedures, researchers strive to make minimally invasive surgery less invasive. Our objective was to apply recent innovations in equipment and surgical approaches to develop the technique and perform laparo-endoscopic single site radical prostatectomy (LESS-RP).

Methods: The technique for LESS-RP was derived by combining existing techniques of standard laparoscopic RP and developing techniques of urological LESS. This incorporated newly available low-profile trocars, flexible instruments and a flexible-tip laparoscope. The procedure was performed through a single 3-cm transverse infra-umbilical incision. LESS-RP was completed successfully via a single operative site without auxiliary needles or trocars. Perioperative variables and postoperative outcomes were recorded and measured.

Results: The operative time was 424 min and the hospital stay was 10 days because of a vesicourethral leak and ileus. The anastomotic leak resolved and the urethral catheter was removed at 4 weeks after surgery. The final pathology showed negative margins and Gleason 3 + 4 pT2c prostatic adenocarcinoma.

Conclusions: LESS-RP is feasible by replicating laparoscopic RP techniques and incorporating the LESS technique with the advent of flexible-tip laparoscopes and flexible instruments. After a learning curve has been overcome, this should be further tested prospectively to compare oncological and functional outcomes with laparoscopic and robotic-assisted RP.

© 2011 Arab Association of Urology. Production and hosting by Elsevier B.V. All rights reserved.

* Corresponding author. Address: The Smith Institute for Urology,
450 Lakeville Road, Suite M41, New Hyde Park, NY 11040, USA.
E-mail address: LRichsto@nshs.edu (L. Richstone).



Introduction

The surgical treatment of prostate cancer has changed dramatically over the past decade, with most prostatectomies carried out using a minimally invasive approach. In 2005, > 10% of all radical prostatectomies (RPs) in the USA were done using robotic-assisted laparoscopic surgery [1]. Only 2 years later, robotic-assisted laparoscopic RP (RALP) was established as the standard for RP [2]. In fact, there are currently more RALPs performed in the USA than open prostatectomies [3]. As laparoscopic and robotic approaches become the standard of care in various urological procedures, the quest for reducing invasiveness and morbidity continues.

In 2002, Gettman et al. [4] introduced 'natural orifice transluminal endoscopic surgery' (NOTES) in urology, with the hypothesis that in the absence of transperitoneal incisions, there would be no external incisional pain and thus recovery would be quicker. In an effort to altogether eliminate transperitoneal incisions, the authors proposed establishing access through abdominal and pelvic viscera. Not surprisingly, this technique was slow to gain acceptance because there was no effective instrumentation and a stable platform, the potential for iatrogenic intraperitoneal complications, and questions about the proper closure of visceral incisions [5]. Realising the limitations of NOTES, laparoscopic surgeons have embraced the possibility of reducing the number of incisions from the standard three-to-six to a single transperitoneal incision in a procedure consensually termed laparo-endoscopic single-site surgery (LESS).

The incorporation of these novel techniques into RP has been hampered by the inherent technical difficulties and intricacies of performing the procedure laparoscopically. Standard laparoscopic and RALP involves placing five to seven ports transperitoneally. These ports are 5–12 mm in length, and with each port comes the compounding risk of bleeding, organ injury during port placement, port-site pain, and subsequent port-site complications, such as hernias and wound infections [6]. LESS has been applied to several procedures, including appendectomy [7], cholecystectomy [8], nephrectomy [9], partial nephrectomy [10], and recent reports of LESS-RP [11,12] have also been published. The aim of the present report is to describe the technique devised at our institution for nerve-sparing LESS-RP, and to contribute to the existing data available on the feasibility of this novel procedure.

Patient and method

A 49-year-old man presented with cT1c prostate cancer with a PSA level of 18.1 ng/mL. He was otherwise healthy and had no previous abdominal surgery. The Gleason score based on his prostate biopsy showed 3 + 4 adenocarcinoma. The patient had a body mass index of 27 kg/m². He elected to undergo minimally invasive RP.

The patient was placed in a Trendelenburg position with low lithotomy stirrups and the arms tucked. Sequential compression devices were placed on both the lower extremities. A single 3-cm transverse infra-umbilical incision was made. Pneumo-insufflation was obtained using a Veress needle. A flexible-tip laparoscope (LTF Series, Olympus Surgical, Orangeburg, NY, USA), two 5-mm Anchorports (Surgique, Orange, CT, USA), and a 12-mm trocar were placed through

separate fascial punctures within the single infra-umbilical incision site. Flexible instruments (Realthand, Novare, Cupertino, CA, USA) were used in addition to standard laparoscopic instruments. A 5-mm and a 10-mm flexible-tip laparoscope (LTF Series) were used during the procedure, with the 5-mm laparoscope reserved for use when 10-mm instruments were required. A surgical assistant was also present throughout the procedure to guide the laparoscope. The standard laparoscopic RP technique, as described previously [13], was adapted to a single operative site. The seminal vesicles were dissected posteriorly after incising the posterior peritoneum. An athermal technique was used to eliminate thermal injury to the pelvic plexus. A 10-mm disposable titanium clip applier was used for hemostasis, and the seminal vesicles were dissected to their tips. The space of Retzius was then entered by dividing the medial umbilical ligaments and urachal remnant. The endopelvic fascia was incised athermally and the levator musculature swept off the lateral aspect of the prostate. The puboprostatic ligaments were divided sharply. The dorsal venous complex was controlled and divided using a laparoscopic linear stapler. The bladder neck was incised using articulating monopolar scissors. The articulating instrument was critical to direct the tip of the instrument posteriorly and avoid incising into the base of the prostate. The lateral prostatic fascia was incised sharply, and after releasing the neurovascular bundles the vascular pedicles were clipped and divided. The prostatic apex was then dissected and the urethra was transected (Fig. 1). The specimen was immediately placed into an entrapment bag. The vesico-urethral anastomosis was completed with 3-0 poliglecaprone 25 sutures with intracorporeal knot tying (Fig. 2). Minimal leak was noticed upon irrigation at the end of the procedure. The specimen was placed in an entrapment bag and extracted through the infra-umbilical site after the fascial incisions were connected. A 10-F drain was placed through the same incision. No additional ports of any size were used for retraction, dissection, or suturing.

Perioperative data were collected prospectively and recorded. Prophylactic subcutaneous heparin was administered throughout the hospital course. Postoperative pain was assessed by the nursing staff using a visual analog scale (VAS) of 0–10, given to the patient both in the postanaesthesia care unit and every 8 h during the remainder of the hospital stay.

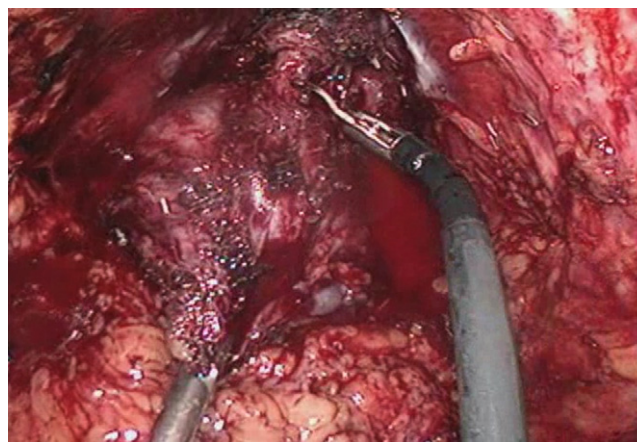


Figure 1 Flexible shears used for prostatic apical dissection and urethral transection.

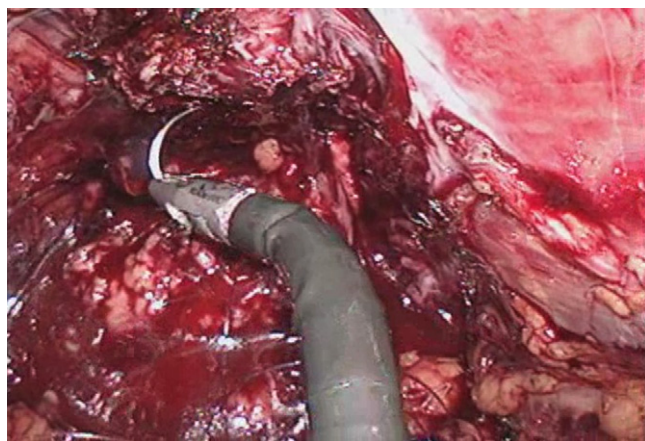


Figure 2 Flexible needle drivers make intracorporeal suturing and tying feasible during LESS.

Information on the analgesic requirements for pain control (in morphine equivalents) was also collected during the hospital stay.

Results

The operative duration of this first LESS-RP was 424 min, with no intraoperative complications; the estimated blood loss was recorded as 100 mL. The postoperative course was complicated because of a vesico-urethral leak and subsequent ileus, resulting in a hospital stay of 10 days. The vesico-urethral leak was managed by placing the urethral catheter on minimal traction and intermittent wall suction for 48 h. The mean VAS scores were highest at 4 days after LESS-RP. The patient was discharged home with a urethral catheter and Jackson–Pratt drain in place.

After resolution of the anastomotic leak based on cystography, the urethral catheter and extravescical drain were removed at 4 weeks after LESS-RP. The final pathology was Gleason 3 + 4 pT2c adenocarcinoma with negative margins. At the 3-month follow-up the serum PSA level was undetectable. The incision made at the umbilicus was found to be well healed with no evidence of wound infection or incisional hernia (Fig. 3). The patient reported almost complete continence (no pads, and rare stress incontinence events) and potency sufficient for penetrative sexual relations at 3 months after surgery. At 3 months the patient responded to a Sexual Health in Men questionnaire, with a score of 17. However, he administered prostaglandin intra-urethral suppositories occasionally.

Discussion

Since its introduction in 1991 [14], minimally invasive urological surgery has been under continuous development, with recent efforts directed at reducing the number of incisions made with standard laparoscopy. There are recent reports of experiences and the perioperative outcomes associated with LESS-RP [11,12]. The purpose of the present study was to describe our technique and confirm the tolerability of this procedure.

LESS-RP exclusively performed through one umbilical incision was first reported by Kaouk et al. in 2008 [11]. Their series included four patients who had single-site surgery using

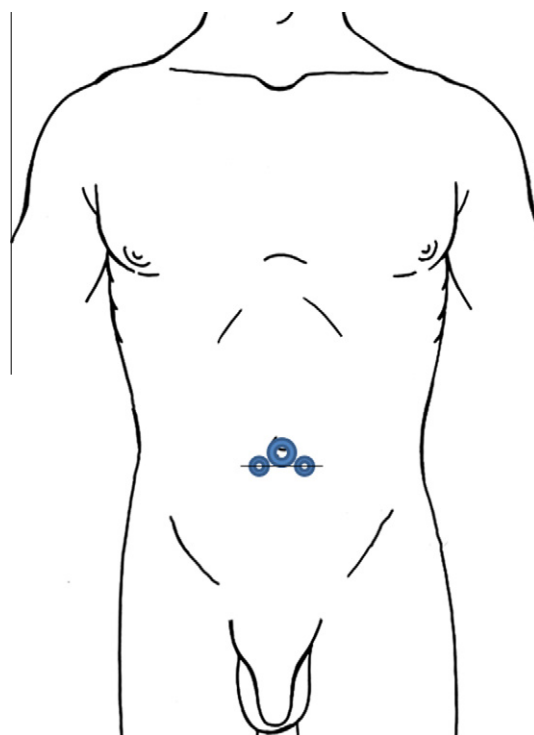


Figure 3 Schematic representation of trocar placement.

the Uni-X Single access (Pnavel Systems, Morganville, NJ, USA) multichannel port in a 1.8-cm umbilical incision. One of the four patients developed a recto-urethral fistula, with no other complications reported. The mean (SD) operative time was 285 (30) min and the estimated blood loss was 285 (131) mL; the length of hospital stay was reported as 2–3 days. The present patient required an operative time of 424 min and had an estimated blood loss of 100 mL. An ileus, secondary to a prolonged vesico-urethral leak, prolonged the patient's hospital stay to 10 days. At 3 months after surgery the patient reported complete continence (pad-free), and erections sufficient for intercourse, which, to our knowledge, represents the first successful nerve-sparing LESS-RP.

Although the benefits of LESS are primarily conjectural at this point, it is postulated that patients have reduced pain levels, with improved cosmetic outcomes. The present patient had VAS scores that gradually increased during the hospital stay and averaged 3.25 on the day of discharge. His analgesic requirements mirrored his VAS scores, with 246 mg of morphine equivalents used throughout the hospital stay. No conclusions can be drawn from these data for tolerability of the procedure, but a well-designed randomized control trial would be needed to determine if there is a significant difference between LESS-RP and RALP.

Transitional animal and cadaveric studies have recently not only shown the feasibility, but have also provided the platform necessary for refining the technique. Barret et al. [12] showed the feasibility of LESS-RP in a fresh human cadaver, and later, LESS-RALP in a human patient. Both the LESS-RP and LESS-RALP were performed using a combination of articulating and standard laparoscopic instruments and trocars placed at the umbilicus, along with an additional 5-mm port placed in the lower abdomen for suctioning, countertraction, and drain placement. The total operative time for the LESS-RALP was

reported as 150 min, and the estimated blood loss was 500 mL, with no complication. Although postoperative data and follow-up information is lacking in this case series, LESS-RALP might resolve the ergonomic limitations we faced during our LESS-RP, particularly during anastomosis, provide better visualization, and provide an avenue for nerve-sparing techniques to be incorporated into the single-site approach. On the contrary, the robotic platform is bulky, with probable clashing of robotic arms, and is associated with higher costs. Notably, the procedures in the present study were performed with the aid of a supplemental port, technically precluding them from being considered LESS procedures.

Although our experience is small, it is critical to report such complicated cases as this burgeoning field advances. Before LESS-RP can be routinely offered to patients, functional and oncological outcomes must be shown to be comparable to current standards. Feasibility reports such as the present one lay the groundwork necessary to show safety and achievability. While this patient retained potency after undergoing a nerve-sparing LESS-RP, patients who are not potent might be better candidates for studies evaluating the feasibility of techniques for radical prostate surgery. Randomized control trials comparing LESS-RP to standard laparoscopic RP, RALP and/or open prostatectomy are necessary to determine the true effect of LESS on oncological and functional outcomes, postoperative pain, and cosmesis. Until such trials are completed, it is imperative that experience with LESS, including complications, be reported accurately.

Conclusion

Based on our initial experience, nerve-sparing LESS-RP is feasible and safe. The learning curve will depend on the surgeons' previous laparoscopic and robotic experience, and might be quite steep for the novice laparoscopic surgeon. Technological advances are vital for the development of LESS techniques: further refinement of existing platforms, flexible-tip laparoscopes, and flexible instruments will drive their development. Prospective randomized data are mandatory to assess outcomes and the ultimate role of LESS-RP and other LESS techniques in urology.

Appendix A. Supplementary data

Supplementary data associated with this article can be found, in the online version, at doi:10.1016/j.aju.2011.03.017.

References

- [1] Descazeaud A, Peyromaure M, Zerbib M. Will robotic surgery become the gold standard for radical prostatectomy? *Eur Urol* 2007;**51**:9–11.
- [2] McCullough TC, Barret E, Cathelineau X, Rozet F, Galiano M, Vallancien G. Role of robotics for prostate cancer. *Curr Opin Urol* 2009;**19**:65–8.
- [3] Box GN, Ahlering TE. Robotic radical prostatectomy: long-term outcomes. *Curr Opin Urol* 2008;**18**:173–9.
- [4] Gettman MT, Cadeddu JA. Natural orifice transluminal endoscopic surgery (NOTES) in urology: initial experience. *J Endourol* 2008;**22**:783–8.
- [5] Bergman S, Melvin WS. Natural orifice transluminal endoscopic surgery. *Surg Clin North Am* 2008;**88**:1131–48.
- [6] Tracy CR, Raman JD, Cadeddu JA, Rane A. Laparoendoscopic single-site surgery in urology. Where have we been and where are we heading? *Nat Clin Pract Urol* 2008;**5**:561–8.
- [7] Inoue H, Takeshita K, Endo M. Single-port laparoscopy assisted appendectomy under local pneumoperitoneum condition. *Surg Endosc* 1994;**8**:714–6.
- [8] Hodgett SE, Hernandez JM, Morton CA, Ross SB, Albrink M, Rosemurgy AS. Laparoendoscopic single site (LESS) cholecystectomy. *J Gastrointest Surg* 2009;**13**:188–92.
- [9] Raman JD, Bensalah K, Bagrodia A, Stern JM, Cadeddu JA. Laboratory and clinical development of single keyhole umbilical nephrectomy. *Urology* 2007;**70**:1039–42.
- [10] Aron M, Canes D, Desai MM, Haber GP, Kaouk JH, Gill IS. Transumbilical single-port laparoscopic partial nephrectomy. *BJU Int* 2009;**103**:516–21.
- [11] Kaouk JH, Goel RK, Haber GP, Crouzet S, Desai MM, Gill IS. Single-port laparoscopic radical prostatectomy. *Urology* 2008;**72**:1190–3.
- [12] Barret E, Sanchez-Salas R, Kasraeian A, Benoist N, Ganatra A, Cathelineau X, et al. A transition to laparoendoscopic single-site surgery (LESS) radical prostatectomy: human cadaver experimental and initial clinical experience. *J Endourol* 2009;**23**:135–40.
- [13] Schuessler WW, Schulam PG, Clayman RV, Kavoussi LR. Laparoscopic radical prostatectomy: initial short-term experience. *Urology* 1997;**50**:854–7.
- [14] Clayman RV, Kavoussi LR, Soper NJ, Dierks SM, Merety KS, Darcy MD, et al. Laparoscopic nephrectomy. *N Engl J Med* 1991;**324**:1370–1.

Editorial comment

The goal of minimally invasive surgery in urology is to achieve the aims of treatment through very small or even no external scar. Recent developments in technology and the introduction of new instruments has encouraged urologists to perform virtually all extirpative and reparative surgeries through a single incision [1–3]. Although this approach poses many difficulties for surgeons, it is very attractive to patients because of the improved quality of life after surgery. Moreover, the only thing that reminds them of their surgery is one small scar. In RP the aim is to comply with the demanding oncological and functional objectives while minimizing the invasiveness of the procedure.

The authors in this article explored the feasibility of LESS-RP, using one 3-cm transverse infra-umbilical incision, and low-profile trocars, flexible instruments and a flexible-tip laparoscope. They describe the technique in detail and present the early outcomes. As this was their first case, the operative time was very long (424 min) and the patient developed a urethrovesical leakage and ileus that prolonged the hospital stay for 10 days, and urethral catheterization for 4 weeks.

The authors are to be congratulated for their courage and patience to do such a lengthy operation, and for their honesty in reporting the complication. There are four previously reported cases of LESS-RP, by Kaouk et al. in 2008 (Ref. [11] in the article).

I remember the extensive debates about laparoscopic RP when it was first described by Guillonnet et al. 2000 [4]. This operation then stood the test of time and became the standard for treating localized prostate cancer. Further developments in the approaches of laparoscopic RP included RALP, which is

currently the most widely used approach for RP (Ref. [2] in the article).

It must be emphasized that LESS-RP is still in its infancy and must be performed by surgeons who have experience in laparoscopic RP. The future will tell whether it will obtain the same acceptance and popularity as the previous approaches or not. There is still a long way to go and there are many obstacles, such as surgical difficulties, availability of less expensive instruments, and a lack of standardized technique. The role of centers with extensive experience in minimally invasive surgery (like the authors' institute) is to lead the urological community through this long and hard way to establish a route for making LESS-RP technically feasible and reproducible. The next step is to conduct randomized controlled trials to compare the surgical and oncological results of different approaches for RP, and thus establish evidence-based guidelines.

Ahmed R. El-Nahas, Assistant Professor of Urology, Urology & Nephrology Center, Mansoura University, Mansoura, Egypt.

References

- [1] Desai MM, Berger AK, Brandina R, Aron M, Irwin BH, Canes D, et al. Laparoendoscopic single-site surgery: initial hundred patients. *Urology* 2009;**74**:805–12.
- [2] White WM, Haber GP, Goel RK, Crouzet S, Stein RJ, Kaouk JH. Single-port urological surgery: single-center experience with the first 100 cases. *Urology* 2009;**74**:801–4.
- [3] Eisenberg MS, Cadeddu JA, Desai MM. Laparoendoscopic single-site surgery in urology. *Curr Opin Urol* 2010;**20**:141–7.
- [4] Guillonneau B, Vallancien. Laparoscopic radical prostatectomy: the Montsouris technique. *J Urol* 2000;**163**:1643–9.