



Study of Placental Chorangiomas in a Tertiary Care Centre

M. Vanishree^{a*#}, Sonti Sulochana^{a^o} and Martin M. S. Salin^{a[≡]}

^a Department of Pathology, Saveetha Medical College, Saveetha Institute of Medical and Technical Sciences, Thandaram - 602 105, Tamil Nadu, India.

Authors' contributions

This work was carried out in collaboration among all authors. All authors read and approved the final manuscript.

Article Information

DOI: 10.9734/JPRI/2021/v33i63B35256

Open Peer Review History:

This journal follows the Advanced Open Peer Review policy. Identity of the Reviewers, Editor(s) and additional Reviewers, peer review comments, different versions of the manuscript, comments of the editors, etc are available here:

<https://www.sdiarticle5.com/review-history/75846>

Original Research Article

Received 20 October 2021
Accepted 27 December 2021
Published 29 December 2021

ABSTRACT

Background: Chorangiomas is a condition in which the number of vascular channels in the noninfarcted, nonischemic areas of the placenta increases dramatically. Chorangiomas rarely occurs in normal pregnancies.

Aims: To study the demography, maternal and fetal causes of chorangiomas.

Study Design: A retrospective descriptive study.

Place and Duration of Study: Total of 73 patients with chorangiomas were studied in Department of Pathology Saveetha Medical College, during the period of August 2020 and February 2021.

Methodology: Study included 73 patients of placental chorangiomas. The clinical history and demographic data was obtained from the patient's medical records. The maternal and fetal causes were studied, and clinico-histopathological correlation was done.

Results: This study includes 73 postnatal women, of which the rate of cesarean section was noted to be 69.8% and the mean value were obtained showed mean gestational age of 37.5 weeks, 70 live births and 3 neonatal deaths; mean placental weight is 480 grams and birth weight 3970 grams. The mean 1 minute and 5 minutes APGAR score is reduced indicating disturbance in fetal vitals immediately after birth.

[#] Postgraduate;

^o Professor;

[≡] Second year MBBS student,

*Corresponding author: E-mail: vanishree.murugavel06@gmail.com;

Conclusion: Chorangiomas are a rare illness, which is associated with an increased risk of prenatal and neonatal morbidity and mortality. So, it should be regarded as a key prognostic indicator of poor pregnancy outcomes and should be essentially reported in the histopathological evaluation.

Keywords: Chorangiomas; maternal hypoxia; placental weight; birth weight; APGAR score.

1. INTRODUCTION

Chorangiomas are a condition in which the number of vascular channels in the noninfarcted, nonischemic areas of the placenta increases dramatically. More than 10 capillaries in more than 10 villi in several areas of the placenta is the traditional description [1]. It's a rare discovery that's usually described as a compensatory response to chronic hypoxia [1], but it's associated to a variety of illnesses, including diabetes, hypertension, and tobacco use. Incidence is higher in women living at high altitudes, in maternal anemia and in smoking women. Also associated with placental abnormalities such as placental abruption, amnion nodosum, villitis and umbilical cord anomalies. Chorangiomas rarely occurs in normal pregnancies. However, its prevalence is 5–7% of all placentas from infants admitted to newborn intensive care units [2] The present study was aimed at determining the association of chorangiomas with pregnancy complications and perinatal outcomes.

2. METHODOLOGY

A retrospective descriptive study was carried out in line with research regulations. Total of 73

patients with chorangiomas were studied in Saveetha Medical College, during the period of August 2020 and February 2021. The clinical history and demographic data was obtained from the patients medical records. The maternal and fetal causes were studied, and clinic-histopathological correlation was done.

3. RESULTS

Demographic data was obtained from the patient's medical records and clinical findings.

The demographic profile of the 73 chorangiomas cases with complete information is summarized in Table 1. The obstetric outcomes are summarized in Table 2. The rate of cesarean section was noted to be 69.8% with the most common indication being nonreassuring fetal heart rate. Majority of neonates were delivered at term with the average gestational age of 37.5 weeks.

In Table 3 the mean value were obtained showed mean gestational age of 37.5 weeks, 70 live births and 3 neonatal deaths; mean placental weight is 1890 grams and birth weight 3970 grams.

Table 1. Demographic profile and maternal clinical history

	CASES(N=73)	PERCENTAGE(%)
AGE		
<18 years old	8	10.9
18-34 years	54	73.9
≥35 years old	11	15.2
GESTATION		
PRETERM <37 weeks	8	10.9
TERM 37-40weeks	38	52.2
POST TERM >40 weeks	27	36.9
PARITY		
Primiparous	28	38.3
Multiparous	45	61.6
COMORBID CONDITIONS		
Gestational Hypertension	7	9.5
Gestational Diabetes mellitus	26	35.6
IUGR	25	34.2

Table 2. Obstetric history

		Cases	Percentage(%)
Gestational age of delivery	<37 weeks	8	10.9
	>37 weeks	67	91.7
Mode of delivery	Vaginal	22	30.1
	Cesarean	51	69.8
Indication for caesarean section	Malpresentation	6	8
	Previous caesarean section	48	65.7
	Labor abnormality	19	26.0

Table 3. Mean values of placental weight , birth weight and apgar score

	Neonates (N=73)
Mean 1 minute APGAR score	7.2
Mean 5 minutes APGAR score	8
Mean Gestational age	37.5
Mean birth weight	3970
Mean placental weight	480
Live births	70
Neonatal deaths	3

Table 4. Mean values in various gestational age

All birth	N	Mean gestational age	Mean Birth weight	Mean Placental weight	Mean Placental weight to birth weight ratio	Mean 1minute APGAR score	Mean 5minutes APGAR score
Gestational age at birth	64	37.5	3450	420	12.17	7.4	8
37	2	37	2480	400	16.12	7.3	8.2
38	1	38	3230	460	14.24	7.2	7.8
39	2	39	3400	500	14.70	7.1	8.1
40	1	40	3650	580	15.89	7.2	8

In Table 4 the mean value in various gestational age were given showing placental weight and fetal birth weight increases in higher gestational age groups. The mean 1 minute and 5 minutes APGAR score is reduced indicating disturbance fetal vitals immediately after birth. Moreover, 1 minute APGAR score is less than 5 minute APGAR score.

3.1 DISCUSSION

Chorangiosis is a vascular abnormality in the placenta that affects the terminal chorionic villi. It's caused by long-term, low -grade hypoxia in the placenta, and it is associated with intrauterine growth restriction (IUGR), diabetes, and gestational hypertension throughout pregnancy. Major fetal complications are congenital anomalies or low Apgar index, neuro-

compromise, fetal growth restriction, neonatal death.

Maternal complications are placental as well as umbilical cord abnormalities including excessively long umbilical cords, true knots, and excessively twisted umbilical cords have also been associated with umbilical cord thrombus. Most common complications are cord compression and circulatory stasis rather than Umbilical vein thrombosis [3].

These findings are associated with fetal, maternal, and placental disorders including preeclampsia, diabetes, hypertension, major congenital anomalies, air pollution, and smoking and has been correlated with fetal morbidity and mortality rates as high as 42% [1]. In recent studies, the pregnancy outcomes are much improved over those suggested by Altshuler in

1984. Adverse events in our study, such as neonatal death at 24 weeks of gestation, are accounted as prematurity without need to invoke chronic hypoxia

Suzuki et al. [4] found an association between maternal blood oxygen saturation in intervillous gaps and the development of chorangiosis by using placental tissue oxygen index values [5]. They postulate that low efficiency of oxygen transfer from maternal to fetal circulation facilitates vascular remodeling in adaptation to low oxygen supply, resulting in chorangiosis.

Placental weight and birth weight of the neonate are widely available measures. The ratio of these two variables is a useful marker of foetal nutrition and utero-placental function [6].

The mean placental weight of 480 g in this study is lower compared to 590 g in Panti AA et al. [7] study (Nigerian study)

The variations in the mean weight of the placenta may be due to variations in the methodology of preparing and weighing the placenta together with cord clamping time [8].

The mean birth weight of the neonate in this study (3970 g) is higher than 3275g in Panti AA et al. [7] study(Nigerian study)

These differences in mean birth weight may be due to altitude; maternal nutrition and maternal diseases [9].

The mean PBWR (placental weight to birth weight ratio) of 14.6% in this study is lower than 18.2% as reported in Panti AA et al. [7] study(Nigerian study)

An abnormally high PBWR (i.e., low fetal weight relative to the placental weight) is thought to indicate an abnormal placenta with impaired function as in human immune deficiency virus infection, obesity, maternal anemia, cigarettes smoking and low socioeconomic status [10-15]. We have shown that cesarean delivery is enriched in patients with placental chorangiosis; however, chorangiosis is not the direct cause. Chorangiosis is a placental marker of antepartum low-grade chronic hypoxia; thus, clinical correlation of entities that may contribute to hypoxia is suggested [16-21].

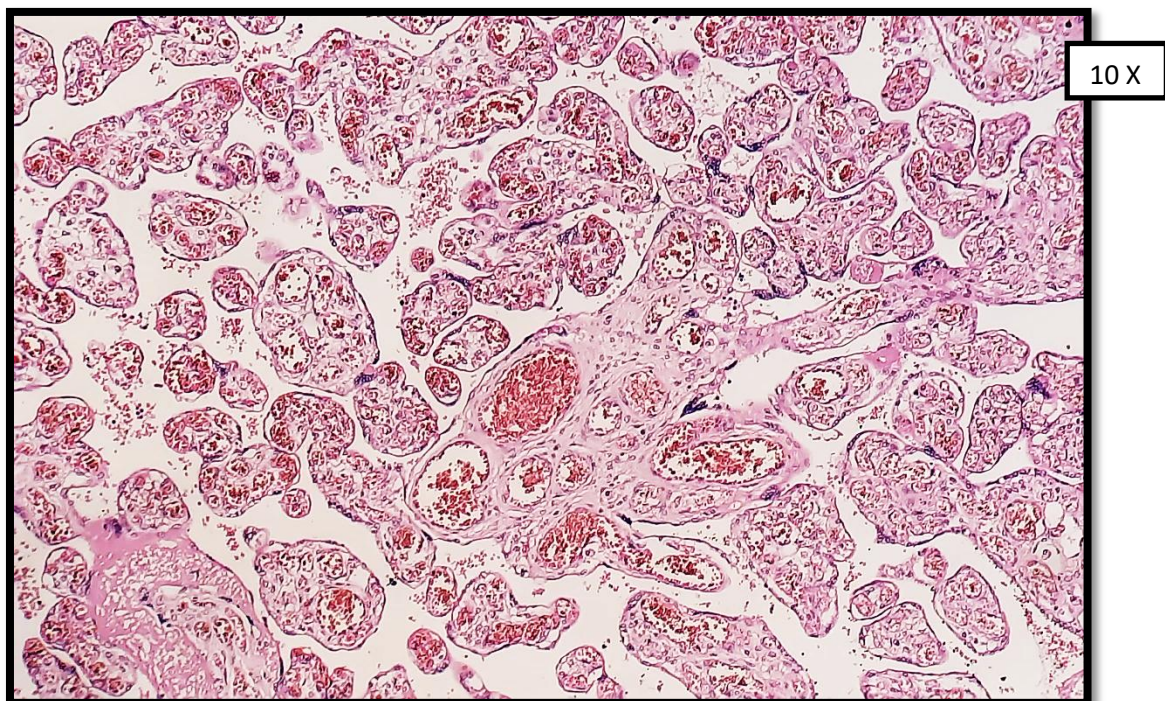


Fig. 1. Chorionic villi with evidence of chorangiosis; more than 10 capillaries in at least 10 terminal villi in low-power fields

3.1.1 Histopathological features

Usually placenta inchorangiosis present as heavy and boggy, weighing about 650 grams, slightly immature placenta ;> 90th percentile for 39 weeks gestational age. Longer umbilical cord about 85 cm. Other placental findings are single umbilical artery and other umbilical cord anomalies, retroplacental hematoma.

Prognostic factors in chorangiosis:

- I. Low Apgar scores
- II. Fetal growth restriction
- III. Neonatal death
- IV. Congenital malformations

3.1.2 Microscopic features

Normal placenta has Normal villi rarely having > 5 capillaries / villous

Criteria for chorangiosis is Altshuler criteria: > 10 capillaries in at least 10 terminal villi in \geq 10 noninfarcted areas in at least 3 low power fields of the placenta (Fig .1). Capillaries have distinct basement membranes but are not surrounded by a continuous layer of pericytes or associated with stromal fibrosis. Sometimes it may be associated with delayed villous maturation, chorangioma(s), villitis of unknown etiology, fetal vascular malperfusion.

4. CONCLUSION

Chorangiosis is a rare illness, which is associated with an increased risk of prenatal and neonatal morbidity and mortality. So, it should be regarded as a key prognostic indicator of poor pregnancy outcomes and should be essentially reported in the histopathological evaluation.

CONSENT

It is not applicable.

ETHICAL APPROVAL

This study was approved by Ethics Committee of Saveetha Medical and Hospital. As this study was a retrospective study, there was no patient's privacy data such as patient name, ID number, telephone and address were involved. Only demographic information and laboratory testing data of patients were collected and analyzed in this study.

COMPETING INTERESTS

Authors have declared that no competing interests exist.

REFERENCES

1. Altshuler GE. Chorangiosis. An important placental sign of neonatal morbidity and mortality. *Archives of Pathology & Laboratory Medicine*. 1984;108(1):71-4.
2. Vafaei H, Karimi Z, Akbarzadeh-Jahromi M, Asadian F. Association of placental chorangiosis with pregnancy complication and prenatal outcome: a case-control study. *BMC Pregnancy and Childbirth*. 2021;21(1):1-8.
3. Fritz MA, Christopher CR. Umbilical vein thrombosis and maternal diabetes mellitus. *The Journal of Reproductive Medicine*. 1981;26(6):320-4.
4. Suzuki K, Itoh H, Kimura S, Sugihara K, Yaguchi C, Kobayashi Y, Hirai K, Takeuchi K, Sugimura M, Kanayama N. Chorangiosis and placental oxygenation. *Congenital Anomalies*. 2009;49(2):71-6.
5. Cunningham FG, Leveno KJ, Bloom SL, Hauth JC, Gilstrap LC, III, Wenstrom KD. *Williams Obstetrics*. 2nd ed. New York: McGraw- Hill; 2005. Implantation, Embryogenesis and Placental Development; 39–90.
6. Yao AC, Moinian M, Lind J. Distribution of blood between infant and placenta after birth. *Lancet*. 1969;2:871–3.
7. Panti AA , Ekele BA, Nwobodo EI, Yakubu A. The relationship between the weight of the placenta and birth weight of the neonate in a Nigerian Hospital. *Nigerian medical journal: journal of the Nigeria Medical Association*. 2012;53(2):80.
8. Njokanma OF, Sule-Odu OA. Intrauterine growth retardation in Nigerian neonates. *Trop J Obstet Gynecol*. 1998;15:25–9.
9. Perry IJ, Beevers DG, Whincup PH, Bareford D. Predictor of ratio of placental weight to fetal weight in multiethnic community. *BMJ*. 1995;310:436–9.
10. Boyd PA, Keeling JW. Raised maternal serum alpha-fetoprotein in the absence of foetal abnormality-placental findings. A quantitative morphometric study. *Prenat Diagn*. 1986;6:369–73.
11. Gichangi PB, Nyongo AO, Temmerman M. Pregnancy outcome and placental weights:

- their relationship to HIV-1 infection. *East Afr Med J.* 1993;70:85–9.
12. Williams LA, Evans SF, Newnham JP. Prospective cohort study of factors influencing the relative weights of the placenta and the newborn infant. *BMJ.* 1997;314:1864–8.
 13. Lao TT, Tam KF. Placental ratio and anaemia in third-trimester pregnancy. *J Reprod Med.* 2000;45:923–8
 14. Schwartz DA. A guest editorial: chorangiosis and its precursors: underdiagnosed placental indicators of chronic fetal hypoxia. *Obstetrical & Gynecological Survey.* 2001;56(9):523-5.
 15. Altshuler GE. Chorangiomas. An important placental sign of neonatal morbidity and mortality. *Archives of pathology & laboratory medicine.* 1984;108(1):71-4
 16. Akbulut M, Sorkun HC, Bir F, Eralp A, Duzcan E. Chorangiomas: the potential role of smoking and air pollution. *Pathology-Research and Practice.* 2009;205(2):75-81.
 17. Shehata F, Levin I, Shrim A, et al. Placenta/ birthweight ratio and perinatal outcome: A retrospective cohort analysis," *BJOG: An International Journal of Obstetrics and Gynaecology.* 2011;118(6):741–747.
 18. Strand KM, Andersen GL, Haavaldsen C, Vik T, Eskild A. Association of placental weight with cerebral palsy: population-based cohort study in Norway," *BJOG: An International Journal of Obstetrics and Gynaecology.* 2015;123(13):2131–2138.
 19. Petersen SS, Khangura R, Davydov D, Zhang Z, Sangha R. Placental chorangiomas: increased risk for cesarean section. *Case Reports in Obstetrics and Gynecology.* 2017;2017.
 20. De La Ossa MM, Cabello-Inchausti B, Robinson MJ. Placental chorangiomas. *Archives of Pathology & Laboratory Medicine.* 2001;125(9):1258. Available:<https://doi.org/10.5858/2001-125-1258-PC>.
 21. Sung DK, Baergen RN. Focal Chorangiomas: Does It Have Clinical and Pathologic Significance?. *Pediatric and developmental pathology : the official journal of the Society for Pediatric Pathology and the Paediatric Pathology Society.* 2019;22(5):406–409. Available:<https://doi.org/10.1177/1093526619830866>

© 2021 Vanishree et al.; This is an Open Access article distributed under the terms of the Creative Commons Attribution License (<http://creativecommons.org/licenses/by/4.0>), which permits unrestricted use, distribution, and reproduction in any medium, provided the original work is properly cited.

Peer-review history:

The peer review history for this paper can be accessed here:
<https://www.sdiarticle5.com/review-history/75846>