



Sex Hormone Disruption and Histological Changes in Testes on Chronic Dichlorvos Exposure in Animal Model

Raymond A. Vhrithire^{1*}, Samuel O. Odeh² and Gideon U. Egesie²

¹*Department of Anatomical Pathology, College of Health Sciences, Benue State University, Makurdi, Nigeria.*

²*Department of Human Physiology, Faculty of Medical Sciences, University of Jos, Jos, Plateau State, Nigeria.*

Authors' contributions

This work was carried out in collaboration among all authors. Authors RAV, SOO and GUE conceptualized, designed and conducted the research. Author RAV analyzed the data and prepared the draft manuscript. All authors read and approved the final manuscript.

Article Information

DOI: 10.9734/JAMMR/2020/v32i930489

Editor(s):

(1) Dr. Babatunde Olanrewaju Motayo, Federal Medical Center and University of Ibadan, Nigeria.

Reviewers:

(1) Valter Javaroni, Hospital Federal Do Andaraí, Brazil.

(2) Orororo, Osuvwe Clement, Edwin Clark University, Nigeria.

Complete Peer review History: <http://www.sdiarticle4.com/review-history/57400>

Original Research Article

Received 14 April 2020

Accepted 20 June 2020

Published 30 June 2020

ABSTRACT

Background: Dichlorvos is an organophosphate used indiscriminately as a pesticide in homes and for agricultural purposes. This study evaluated the effects of its low dose sub-lethal chronic exposure on male reproductive function using an animal (*Rattus norvegicus*) model.

Methodology: Three groups of rats were given dichlorvos at the dosages of 0.28 mg/kg, 0.56 mg/kg and 1.68 mg/kg respectively on alternate days. The control group was given only plain drinking water. The experiment lasted for 50 weeks.

Results: Dichlorvos induced a dosage variation effect on blood levels of follicle stimulating hormone but this was insignificant on levels of luteinizing hormone, oestrogen, progesterone and dihydrotestosterone. Prolonged treatment with dichlorvos had no overall influence on luteinizing hormone levels. The major histological findings in descending order of frequency included tubular atrophy and degeneration, germ cell depletion, germ cell exfoliation, tubular necrosis, spermatid retention and Leydig cell hyperplasia, each scored on a semi-quantitative scale. After 50 weeks of

*Corresponding author: E-mail: akp4ray@yahoo.com;

dichlorvos treatment, progesterone and oestrogen blood levels both had strong positive correlations with the frequency of germ cell exfoliation and residual bodies in the testes. In contrast, there was no statistically significant correlation between blood levels of follicle stimulating hormone, luteinizing hormone and dihydrotestosterone and the histological findings.

Conclusion: This research evaluated the chronic effect of low dichlorvos exposure on reproductive function using an animal model. There was a strong positive correlation between progesterone and germ cell exfoliation and residual bodies. Oestrogen also correlated with germ cell exfoliation, depletion and presence of residual bodies. Furthermore, the correlation between the blood hormone levels and histological changes in the testes was largely unpredictable.

Keywords: Dichlorvos exposure; chronic dichlorvos ingestion; hormone disruption; testes histology.

1. INTRODUCTION

Normal reproductive function in males, including spermatogenesis, involves the deployment and interplay between a complex assortment of peptide and steroid hormones [1]. Spermatogenesis, although orchestrated in the germinal epithelium of the testes, depends on a dynamic but delicate balance among the hypothalamus-pituitary-gonadal axis hormones which is maintained by a subtle feedback mechanism [2]. This balance plays a pivotal role in the synthesis, secretion, transport, metabolism, binding and action of these hormones.

Spermatogenesis is primarily driven by the gonadotropins, follicle stimulating hormone (FSH) and luteinizing hormone (LH). These hormones are produced upon stimulation of the anterior pituitary by the gonadotropin releasing hormone (GnRH), a decapeptide produced by the hypothalamus and released in a pulsatile manner into the pituitary portal circulation.

Once in circulation, luteinizing hormone (LH) triggers a cascade of downstream effects mediated by the second messenger, cyclic adenosine monophosphate (cAMP), leading to the formation of testosterone by the interstitial cells of Leydig. The testicular germinal cells begin to divide in response to the presence of this hormone. The follicle stimulating hormone, on the other hand, acts on the Sertoli cells to engender spermiogenesis.

A horde of environmental toxins, industrial, agricultural or domestic chemicals, have been known to perturb the hypothalamic – pituitary – gonadal axis by disrupting the delicate balance between the hormones [3]. These include substances such as organophosphates used as pesticides [4]. Dichlorvos (commonly sold as Sniper) is used indiscriminately as a pesticide in

homes and for agricultural purposes in Nigeria and most of sub-Sahara Africa. Worldwide consumption of pesticides for agricultural use is constantly rising [5]. And the consequent human health impact of exposure to these substances is equally enormous [6]. Dichlorvos is dimethyl 2,2-dichlorovinyl phosphate (DDVP) which is an organophosphate. Organophosphates have been documented to induce a wide range of adverse health effects from mild allergies, rashes, breathing difficulties, neurotoxicity to reproductive abnormalities and neoplastic diseases [7]. The residues of these substances appear to be ubiquitous and have been reported to be present in water [8], vegetables [9] and food [10] consumed by humans. The effects of its acute toxicity are well known and are outside the scope of this paper. Similarly, most of the studies published on effects of this substance on reproductive functions are based on short term studies. Much fewer papers explored the effects of these substances in a manner which simulate the prolonged low dose continuous exposure of the people living in predominantly agricultural communities or low income communities where dichlorvos is considered a cheaper alternative for control of mosquitoes and other pests in homes. It was hypothesised by the authors that an exposure of this nature could potentially disrupt normal hormonal pattern and induce structural cellular effects in the testes; and that there might be a direct demonstrable correlation between hormone disruptions and induced adverse histological changes.

2. MATERIALS AND METHODS

Male Wistar albino rats (*Rattus norvegicus*) obtained from the Animal House of the University of Jos, Jos, Plateau State, Nigeria, were used for this work. The animals were housed in spacious cages under the same conditions of temperature and humidity. There was an average of 12 hours of light daily. They also received adequate

amounts of pellet feeds daily until they reached maturity and their weight ranged 120–200 g before commencement of treatments.

The treatment substance was commercially available dichlorvos (2, 2, dichlorovinyl dimethyl phosphate) sold as Sniper[®], with purity of 98%. The established lethal dose (LD₅₀) of 56 mg/kg for dichlorvos was used as reference (California Environmental Protection Agency, 1996) for the calculation of treatment regimes.

Four groups of animals were given the following treatments for evaluation of hormonal effects of dichlorvos. The control group (Group 1) was given plain drinking water. Group 2 were received 0.28 mg/kg (0.5% LD₅₀) while Group 3 and 4 each had 0.56 mg/kg (1% LD₅₀) and 1.68 mg/kg (3% LD₅₀) respectively using an oro-gastric gavage tube. Treatments were administered on alternate days for the period of fifty weeks. At spaced intervals of 16.5 weeks, five animals were euthanized by cervical dislocation and blood samples were collected for blood hormonal assay by intra-cardiac puncture and aspiration. Blood levels of follicle stimulating hormone, luteinizing hormone, oestrogen, dihydrotestosterone and progesterone were evaluated using enzyme linked immunosorbent assay kit (Accu-Bind Elisa Microwells, manufactured by Monobind Inc., 100 North Pointe Drive, Lake Forest California 92630, USA).

The testes were dissected out, fixed in buffered formal saline and processed routinely. Sections, 3 – 5µ thick, were made from the paraffin tissue blocks and stained with hematoxylin and eosin. The glass slides were evaluated using Leica DM 750 binocular light microscope, (Leica Microsystems Limited, Switzerland). Microscope images were taken using Leica ICC50 W camera mounted on the light microscope and the digital images were acquired and processed by Leica Application Suite, version 3.0.0, Build 629 (released in 2013, Leica Microsystems Limited, Switzerland). The histological evaluation of the slides was based on established guidelines and the parameters assessed included tubular atrophy or degeneration, germ cell depletion, germ cell exfoliation, tubular vacuolation, tubular contraction, tubular dilation, spermatid retention, residual bodies, tubular necrosis, tubular neutrophilic inflammation, tubular granulomatous inflammation, perivascular necrosis or inflammation, interstitial oedema, multinucleated giant cells, sperm stasis or spermatocoele, tubular amyloid, tubular mineralization

(calcification), Leydig cell atrophy, Leydig cell hypertrophy, Leydig cell adenoma, rete testis hyperplasia, epididymis degeneration or atrophy [11,12]. A semi-quantitative scoring system was adapted to grade each of the parameters evaluated in the seminiferous tubules as follows: score 0 (parameter absent), score 1 (minimal or <5% area of tubule affected), score 2 (slight or 5-25% tubule area affected), score 3 (moderate or 25-50% tubule area affected), score 4 (marked or 50-75% tubule area), score 5 (severe or >75% tubule area affected) [12].

The data obtained from this research was managed and analysed using two statistical software applications, IBM SPSS Statistics, version 23 (Release date 2015; IBM Corporation, Armonk, New York, USA) and Microsoft Excel, version 16.0 (Release date 2016; Microsoft Corporation, Redmond, Washington).

3. RESULTS

Sixty male Wistar albino rats were allotted for this aspect of the research, but following an attrition rate of 16.67%, fifty were used for this evaluation.

3.1 Blood Hormone Level Analysis

The effects of dosage variation and duration of treatment of the rats with dichlorvos were assessed using Kruskal – Wallis H test for multiple comparisons since blood levels of the hormones violated requirements of normality and homogeneity for use of parametric tools.

The median FSH blood levels in the controls were higher ($Mdn_{Control} = 0.650$) than in the treated animals ($Mdn_{Group 2}$, $Mdn_{Group 3}$ & $Mdn_{Group 4} = 0.00$). Kruskal – Wallis H test showed that a statistically significant difference existed between the blood levels of FSH obtained at different dichlorvos treatment dosages, $H(3) = 11.79$, $p = 0.008$, with a significance (α) level of 0.05. A further post hoc Mann Whitney U test with Bonferroni correction rejected the null hypothesis that there was no statistical difference in the distribution of FSH levels on pairwise comparison between the control rats and those given 0.28mg/kg (Group 2) or 0.56mg/kg (Group 3) of dichlorvos ($p = 0.022$, $p = 0.020$, respectively). However, the distributions of LH, oestrogen, DHT and progesterone blood levels were similar in all the experimental groups ($p = 0.237$, $p = 0.097$, $p = 0.517$ and $p = 0.209$, respectively) indicating lack of statistically significant effect of dichlorvos administration on these hormones.

There were statistically significant differences in the blood levels of follicle stimulating hormone ($H(2) = 8.448, p = 0.015$), oestrogen ($H(2)=19.733, p=0.000$), dihydrotestosterone ($H(2) = 24.036, p = 0.000$) and progesterone ($H(2)=18.977, p=0.000$) across 17 weeks, 34 weeks and 50 weeks of experimentation. There was no significant change in LH levels throughout the period ($H(2)=4.239, p = 0.120$). Thus, dichlorvos administration only altered the blood levels of the four hormones and had no notable influence on luteinizing hormone. Post hoc tests were performed to determine the time intervals with differences in significant hormone levels. It was found that FSH, oestrogen and progesterone had no significantly different blood levels when compared with controls between 17 to 34 weeks ($p = 1.000, p = 1.000, p=0.250$, respectively) while a similar lack of difference was found between 34 to 50 weeks for DHT ($p = 0.761$) suggesting an early onset of effect of dichlorvos on DHT and late onset on the other hormones affected.

3.2 Histological Evaluation of the Testes

The histological parameters which were found at the three time intervals are shown on the Table 1 below. Tubular dilation, tubular amyloid, calcification, Leydig cell atrophy, Leydig cell adenoma, rete testes hyperplasia, and disorders in the epididymis, prostate and seminal vesicles were absent in all the groups throughout the period of study. Tubular atrophy/degeneration, germ cell depletion, germ cell exfoliation and Leydig cell hyperplasia were the major changes seen in this study. There was a semi-quantitative assessment on a six-point scale and scores were awarded to each histological finding to indicate its degree of grade or severity. Fig. 1 is a bar chart which plotted the sum of these scores for each histological parameter. As shown on Table 2, 88.9% ($n=16/18$), 94.1% ($n=16/17$) and 86.7% ($n=13/15$) of the animals at the end of 17-, 34- and 50-week intervals respectively had tubular atrophy or degeneration. Overall, tubular atrophy or degeneration was present in 90% ($n=45/50$) of all the animals in this study. The relative frequencies of the rest of the histological findings are presented on Table 2 below.

Did administration of dichlorvos induce significant histological changes noted at the sample specimen collection intervals during the period of treatment? Having violated assumptions of normality and homogeneity, the values obtained from the semi-quantitative scoring of the gravity

of the histological parameters were tested for differences in distribution using the Kruskal Wallis H test. There were no differences observed in the control group at the designated time intervals ($p < 0.05$) except with germ cell depletion ($p = 0.038$), in which the difference was found between 17 and 34 weeks ($X^2(2) = 5.500, p = 0.032$) on Mann Whitney U test with Bonferroni correction.

In the Group 2 animals, significant differences were found in tubular atrophy/degeneration, vacuolation and contraction, and Leydig cell hyperplasia ($p < 0.05$).

In the Group 3 animals, statistically significant differences were found only in the scores for residual bodies between 17 and 50 weeks on pairwise analysis ($p = 0.032$). Similar to Group 2, the Group 4 animals demonstrated differences in tubular atrophy/degeneration, vacuolation and contraction, and Leydig cell hyperplasia ($p < 0.05$).

3.3 Correlation between Blood Hormones and Histological Findings

Spearman's rho correlation coefficient was used to assess if any correlation existed between the sex hormone levels and scores of the histological findings ($H_0: \rho_s = 0, H_1: \rho_s \neq 0$) in the treatment groups. There was a strong positive monotonic relationship between FSH and DHT at 17 weeks ($r_s = 0.616, n = 17, p = 0.008$), and between FSH and LH at 50 weeks ($r_s = 0.730, n = 16, p = 0.001$). At 34 weeks, DHT had a statistically significant moderate negative correlation with LH ($r_s = - 0.524, n = 19, p = 0.021$). There was a very strong correlation between germ cell depletion and tubular vacuolation at 17 weeks ($r_s = 0.867, n = 18, p = 0.000$); between germ cell depletion and Leydig cell hyperplasia at 34 weeks ($r_s = 0.873, n = 18, p = 0.000$). At fifty weeks, there was a strong negative correlation between germ cell exfoliation and residual bodies ($r_s = - 0.829, n = 17, p = 0.000$), and a strong positive correlation between tubular contraction and Leydig cell hyperplasia ($r_s = 0.848, n = 17, p = 0.000$).

Table 3 shows details of the statistically significant correlation coefficients found in this study, and remarks on the strength of the relationships between the hormones and the histological findings. After 50 weeks of dichlorvos treatment, progesterone and oestrogen blood levels both had strong positive correlations

with the frequency of germ cell exfoliation and residual bodies in the testes (Table 3c). In contrast, there was no statistically significant correlation between blood levels of follicle stimulating hormone, luteinizing hormone and dihydrotestosterone and histological findings.

Table 3. Correlation between blood hormone levels and histological findings. Spearman's rho correlation coefficient was used to explore the association between the parameters. The table includes a comment on the strength of the

association, as weak, moderate, strong, or very strong.

This entity represents the most common histological alteration induced by chronic dichlorvos treatment in this experiment. As shown on the photomicrograph, it is characterised by significant attenuation of the number of germ cells. Some of the seminiferous tubules are empty with complete burn out of the germ cells while others have reduced number of layers of the germ cells. *Hematoxylin and eosin stain, x 10 objective magnification.*

Table 1. Occurrence of histological parameters assessed in testes

	Present	Absent
17 weeks	Tubular atrophy or degeneration [§] , germ cell depletion, germ cell exfoliation [§] , tubular vacuolation, spermatid retention [§] , residual bodies [§] , tubular necrosis, tubular granulomatous inflammation, Leydig cell hyperplasia, tubular neutrophilic inflammation, interstitial oedema, multinucleated giant cells.	Perivascular necrosis or inflammation, tubular contraction, tubular dilation, sperm stasis or spermatocele, tubular amyloid, tubular mineralization (calcification), Leydig cell atrophy, Leydig cell adenoma, rete testis hyperplasia, epididymis degeneration or atrophy, prostate abnormalities, seminal vesicle abnormalities.
34 weeks	Tubular atrophy or degeneration [§] , germ cell depletion [§] , germ cell exfoliation [§] , tubular vacuolation, spermatid retention, residual bodies [§] , tubular necrosis, [§] tubular granulomatous inflammation, Leydig cell hyperplasia, tubular contraction, tubular neutrophilic inflammation	Perivascular necrosis or inflammation, tubular dilation, interstitial oedema, multinucleated giant cells, sperm stasis or spermatocele, tubular amyloid, tubular mineralization (calcification), Leydig cell atrophy, Leydig cell adenoma, rete testis hyperplasia, epididymis degeneration or atrophy, prostate abnormalities, seminal vesicle abnormalities
50 weeks	Tubular atrophy or degeneration [§] , germ cell depletion [§] , germ cell exfoliation [§] , tubular vacuolation, spermatid retention [§] , residual bodies [§] , tubular necrosis, tubular granulomatous inflammation, Leydig cell hyperplasia, tubular contraction, interstitial oedema, multinucleated giant cells, sperm stasis or spermatocele.	Perivascular necrosis or inflammation, tubular dilation, tubular neutrophilic inflammation, tubular amyloid, tubular mineralization (calcification), Leydig cell atrophy, Leydig cell adenoma, rete testis hyperplasia, epididymis degeneration or atrophy, prostate abnormalities, seminal vesicle abnormalities.

[§] This histological feature was also present in some of the control group animals

Table 2. Relative frequencies of histological findings

	Histological features	17 weeks (n=18)		34 weeks (n=17)		50 weeks (n=15)		Sum	%
		X [¶]	% (x/n*100) [§]	X [¶]	% (x/n*100) [§]	X [¶]	% (x/n*100) [§]		
1	Tubular Atrophy/Degeneration	16	88.9	16	94.1	13	86.7	45	90
2	Germ Cell Depletion	13	72.2	16	94.1	13	86.7	42	84
3	Germ Cell Exfoliation	13	72.2	16	94.1	13	86.7	42	84
4	Tubular Vacuolation	3	16.7	6	35.3	6	40.0	15	30
5	Tubular Contraction	0	0.0	3	17.6	8	53.3	11	22
6	Tubular Dilatation	0	0.0	0	0.0	0	0.0	0	0
7	Spermatid Retention	8	44.4	7	41.2	10	66.7	25	50
8	Residual Bodies	5	27.8	5	29.4	10	66.7	20	40
9	Tubular Necrosis	5	27.8	9	52.9	12	80.0	26	52
10	Tubular Inflammation: Neutrophilic	0	0.0	0	0.0	4	26.7	4	8
11	Tubular Inflammation: Granulomatous	0	0.0	0	0.0	0	0.0	0	0
12	Perivascular Necrosis/Inflammation	0	0.0	0	0.0	0	0.0	0	0
13	Interstitial Oedema	0	0.0	0	0.0	1	6.7	1	2
14	Multinucleated Giant Cells	0	0.0	0	0.0	1	6.7	1	2
15	Sperm Stasis/Spermatocoele	0	0.0	2	11.8	2	13.3	4	8
16	Tubular Amyloid	0	0.0	0	0.0	0	0.0	0	0
17	Tubular Mineralization (Calcification)	0	0.0	0	0.0	0	0.0	0	0
18	Leydig Cell Atrophy	0	0.0	0	0.0	0	0.0	0	0
19	Leydig Cell Hyperplasia	5	27.8	9	52.9	11	73.3	25	50
20	Leydig Cell Adenoma	0	0.0	0	0.0	0	0.0	0	0
21	Rete Testis Hyperplasia	0	0.0	0	0.0	0	0.0	0	0
22	Epididymis Degeneration/Atrophy	0	0.0	0	0.0	0	0.0	0	0
23	Prostate abnormalities	0	0.0	0	0.0	0	0.0	0	0
24	Seminal Vesicle abnormalities	0	0.0	0	0.0	0	0.0	0	0

¶ Values denote the number of animals in which each histological feature was found.

§ The percentages are expressed as the proportion of the number of sacrificed at 17, 34 or 50 weeks; n=sum of animals; x=the number of animals with the histological parameter under consideration

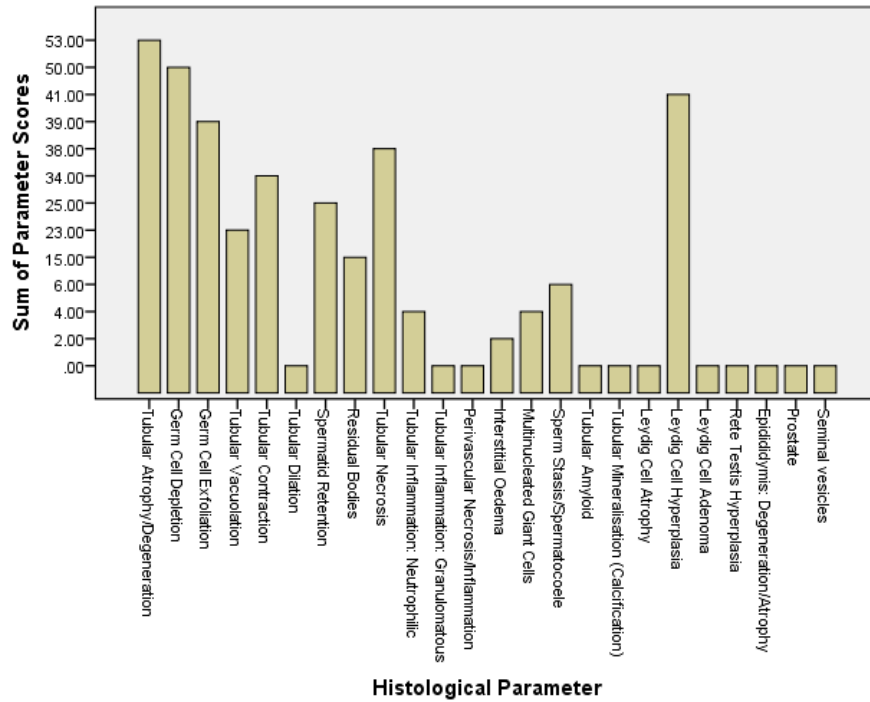


Fig. 1. Overall frequency of each histological finding. Tubular atrophy or degeneration was the most common entity in the testes

Table 3a. Correlation values at 17 weeks

	Correlated parameters	r _s	p	n	Strength [¶]
1	FSH and DHT	0.616**	0.008	17	S
2	FSH and tubular atrophy/degeneration	0.657**	0.004	17	S
3	FSH and spermatid retention	0.525*	0.031	17	M
4	Tubular atrophy/degeneration and germ cell depletion	0.563*	0.015	18	M
5	Tubular atrophy/degeneration and tubular vacuolation	0.583*	0.011	18	M
6	Tubular atrophy/degeneration and germ cell exfoliation	0.587*	0.010	18	M
7	Tubular atrophy/degeneration and spermatid retention	0.587*	0.010	18	M
8	Germ cell depletion and tubular vacuolation	0.867**	0.000	18	VS
9	Germ cell depletion and spermatid retention	0.681**	0.002	18	S
10	Germ cell depletion and germ cell exfoliation	0.554*	0.017	18	M
11	Germ cell depletion and tubular necrosis	0.508*	0.031	18	M
12	Germ cell exfoliation and tubular vacuolation	0.766**	0.000	18	S
13	Germ cell exfoliation and spermatid retention	0.633**	0.005	18	S
14	Germ cell exfoliation and tubular necrosis	0.515*	0.029	18	M
15	Tubular vacuolation and spermatid retention	0.742**	0.000	18	S
16	Spermatid retention and residual bodies	0.544*	0.020	18	M
17	Spermatid retention and tubular necrosis	0.663**	0.003	18	S
18	Residual bodies vs. tubular necrosis	0.577*	0.012	18	M

r_s: Spearman's rho correlation coefficient, p: calculated significance value, n: sample size.

** Correlation is significant at the 0.01 level (2-tailed).

* Correlation is significant at the 0.05 level (2-tailed).

¶ M: moderate correlation, S: strong correlation, VS: very strong correlation

Table 3b. Correlation values at 34 weeks

	Correlated parameters	r_s	p	n	Strength
1	LH vs. DHT	-0.524*	0.021	19	M
2	Progesterone and spermatid retention	0.547*	0.019	18	M
3	Tubular atrophy/degeneration and germ cell exfoliation	0.502*	0.034	18	M
4	Tubular atrophy/degeneration and tubular vacuolation	0.530*	0.024	18	M
5	Tubular atrophy/degeneration and tubular necrosis	0.582*	0.011	18	M
6	Tubular atrophy/degeneration and tubular contraction	0.483*	0.042	18	M
7	Tubular atrophy/degeneration and Leydig cell hyperplasia	0.685**	0.002	18	S
8	Germ cell depletion and Tubular atrophy/degeneration	0.531*	0.023	18	M
9	Germ cell depletion and tubular vacuolation	0.550*	0.018	18	M
10	Germ cell depletion and tubular contraction	0.611**	0.007	18	S
11	Germ cell depletion and tubular necrosis	0.510*	0.031	18	M
12	Germ cell depletion and Leydig cell hyperplasia	0.873**	0.000	18	VS
13	Germ cell exfoliation and spermatid retention	0.697**	0.001	18	S
14	Tubular contraction and Leydig cell hyperplasia	0.524*	0.025	18	M
15	Residual Bodies and tubular necrosis	-0.695**	0.001	18	S
16	Residual Bodies and sperm stasis/spermatocoele	0.750**	0.000	18	S
17	Residual bodies and Leydig cell hyperplasia	0.529*	0.024	18	M
18	Leydig cell hyperplasia and tubular vacuolation	0.663**	0.003	18	S
19	Leydig cell hyperplasia and tubular necrosis	0.529*	0.024	18	M

r_s: Spearman's rho correlation coefficient, p: calculated significance value, n: sample size.

** Correlation is significant at the 0.01 level (2-tailed).

* Correlation is significant at the 0.05 level (2-tailed).

[¶]M: moderate correlation, S: strong correlation, VS: very strong correlation

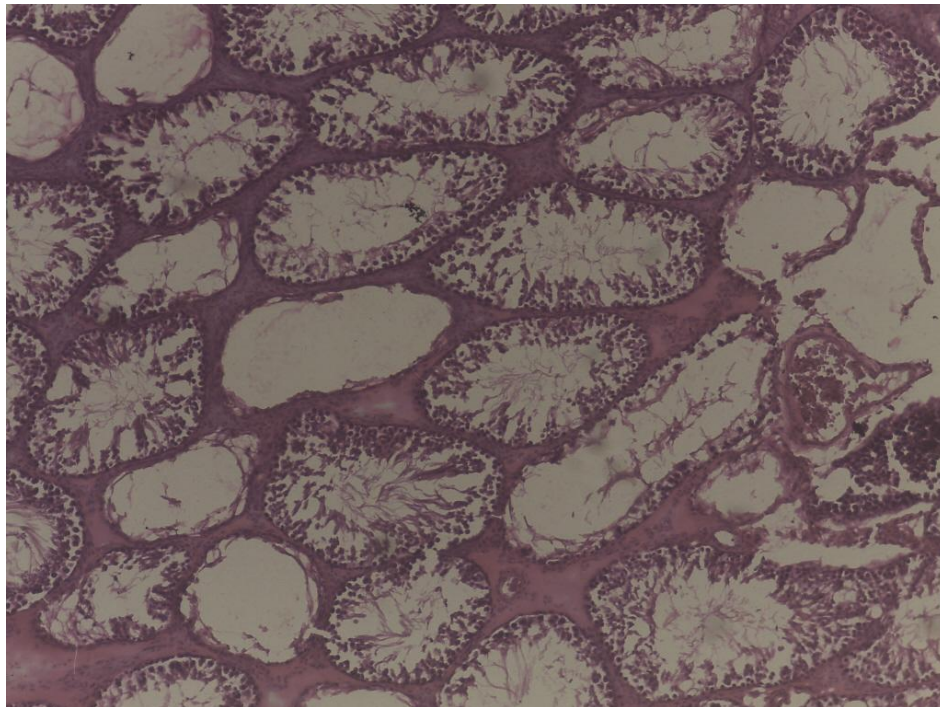


Fig. 2. Tubular atrophy/degeneration

Table 3c. Correlation values at 50 weeks

	Correlated parameters	r_s	p	n	Strength
1	FSH and LH	0.730**	0.001	16	S
2	Oestrogen and progesterone	0.577*	0.019	16	M
3	Oestrogen and tubular atrophy/degeneration	-0.533*	0.034	16	M
4	Oestrogen and germ cell depletion	-0.717**	0.002	16	S
5	Oestrogen and germ cell exfoliation	0.671**	0.004	16	S
6	Oestrogen and residual bodies	-0.771**	0.000	16	S
7	Progesterone and germ cell exfoliation	0.600*	0.014	16	S
8	Progesterone and residual bodies	-0.744**	0.001	16	S
9	Tubular atrophy/degeneration and germ cell depletion	0.747**	0.001	17	S
10	Germ cell depletion and germ cell exfoliation	-0.553*	0.021	17	M
11	Germ cell depletion and tubular contraction	-0.691**	0.002	17	S
12	Germ cell depletion and residual bodies	0.698**	0.002	17	S
13	Germ cell depletion and sperm stasis/spermatocoele	0.573*	0.016	17	M
14	Germ cell exfoliation and residual bodies	-0.829**	0.000	17	VS
15	Tubular vacuolation and sperm stasis/spermatocoele	0.583*	0.014	17	M
16	Tubular contraction and tubular necrosis	0.561*	0.019	17	M
17	Tubular contraction and Leydig cell hyperplasia	0.848**	0.000	17	VS
18	Spermatid retention and tubular necrosis	0.669**	0.003	17	S
19	Spermatid retention and multinucleated giant cells	0.542*	0.025	17	M
20	Spermatid retention and interstitial oedema	0.542*	0.025	17	M
21	Residual bodies and sperm stasis/spermatocoele	0.566*	0.018	17	M

r_s: Spearman's rho correlation coefficient, *p*:calculated significance value, *n*: sample size.

** Correlation is significant at the 0.01 level (2-tailed).

* Correlation is significant at the 0.05 level (2-tailed).

¶M: moderate correlation, S: strong correlation, VS: very strong correlation

4. DISCUSSION

Follicle stimulating hormone (FSH) supports spermatogenesis quantitatively, and in Sertoli cells, acts synergistically with testosterone to stimulate the cells to activate signals for maturation of germ cells [13]. In this research, there was statistically significant difference observed between the level of FSH in the controls and those in the experimental groups given dichlorvos (DDVP). The point at which this effect took place in the hypothalamus-pituitary-gonadal axis is, however, outside the scope of this work. The blood level of FSH found in the experimental groups had a lower median value than in controls. Dirican et al. documented a decrease in FSH in rats treated with dichlorvos [14]. However, unlike in this present study where there was no dose related effect with the other hormones blood levels, these researchers found a decrease in the levels of LH and testosterone [14].

Krause et al had previously observed that the level of FSH and LH levels remained the same

while testosterone levels decreased on exposure of adult male rats to dichlorodiphenyltrichloroethane (DDT), DDVP and malathion. This group suggested that DDVP had a direct cytotoxic effect on the testes [15]. The levels of FSH, oestrogen, DHT and progesterone varied over time in our study. The duration of treatment appeared not to have any influence on LH levels. Sharma et al., however, observed a decrease in FSH, LH and testosterone after 40 days administration of dichlorvos suggesting loss of feedback control [16].

A case –control human study targeting occupational exposure to pesticides in 51 pesticide sprayers found that FSH levels increased in the workers when compared to the controls. This paper was limited in scope because it failed to specify the names or kinds of the pesticides implicated to enable readers place the results in the proper perspective. The LH and testosterone levels were unaffected similar to the findings in our study [17]. In contrast, another study which assessed the hormone levels of

farmers exposed to pesticides showed a significant decrease in FSH, LH and testosterone [18].

These studies from animals and humans show wide variations in the impact on reproductive physiology following exposure to organophosphates. This observation may not be explained in a simplistic manner since a few authors have noted effects extending beyond the hypothalamus-pituitary-gonadal hormonal pathway to complex metabolic pathways in the liver. Dichlorvos administration was found to induce widespread disruption of energy metabolism in zebrafish [19], and reduced hepatic glucokinase while increasing also the glucokinase mRNA levels [20]. Glucokinase has been identified as an important component of glucose sensing pathways in the cells of anterior pituitary gland of rats and monkeys [21]. The significance of these findings was reviewed in detail in a recent paper [22]. The pulsatile stimulation of hypothalamic cells for release of gonadotropin releasing hormone (GnRH) is regulated by an upstream population of cells found in the arcuate nucleus that co-express the neuropeptides kisspeptin, neurokinin B and dynorphin (known as KNDy cells) [23,24]. GnRH receptor activation results in phospholipase C activation, inositol 1, 4, 5-tris-phosphate (IP3) mediated endoplasmic reticulum calcium release leading to gonadotropin synthesis and release [25,26]. Co-localisation of glucokinase and the hormones in the same cells found in a study suggests that the release of follicle stimulating hormone and luteinizing hormone is interlaced with glucose homeostasis [27]. In addition, KNDy cells express receptors for insulin and leptin [24], further supporting the suggestion that disruption of energy pathways may partly explain the hormonal disruption observed with DDVP. Again, the complexity of these interactions may be the cause of the attenuation of feedback control documented in some studies [16].

In summary, the literature on the impact of chronic dichlorvos exposure on reproductive physiology is probably by direct cytotoxicity, or indirectly via neural pathways with inhibition of cholinesterase [28], dopaminergic neurodegeneration [29], oxidative stress [14,30] and disruption of multiple metabolic [19] and genetic pathways [31].

A stable germinal population, a major determinant of fertility, depends on a balance between committed cell division and attrition

through apoptosis and anoikis [32]. Loss of germ cells may manifest in various ways. Tubular atrophy or degeneration, germ cell depletion, germ cell exfoliation and Leydig cell hyperplasia were the major changes observed in this experiment. Ninety percent of the animals had tubular atrophy or degeneration.

There has existed in the biomedical literature a relative gap with absence of comprehensive detailed descriptions of testicular histological changes induced on chronic exposure to dichlorvos. Driven by the aim of finding substances which can ameliorate effects of exposure and possibly improve fertility indices, less attention has been paid to structural alterations. It is believed by the author that the relative paucity of explicit explanations linking structural changes to measured functional alterations observed in most papers on this subject is predicated on less attention to histological changes despite documented evidence that poor sperm parameters is largely due to loss or changes in germ cells. In the experiment conducted by Dirican et al, with dichlorvos and vitamins were given to rats, oedema was noticed after four weeks and necrosis, after seven weeks, was found in some seminiferous tubules. The vitamins appeared not to have the desired protection in the longer term as necrosis was also observed in those administered the dichlorvos and vitamins. Although the experiment ran for seven weeks, necrosis and interstitial oedema were the only histological alterations described [14]. In another experiment to find out if selenium had protective properties against methyl parathion, an organophosphate (similar to dichlorvos), a group of rats were treated with both substances for eight weeks. The workers documented necrosis, vacuolation, disruption of the seminiferous epithelium and loss of germ cells [33]. While germ cells are readily affected, Sertoli cells appear to be more resilient as was also noted in the present study [34]. However, some workers documented Sertoli cell destruction and disorganisation of germinal epithelium after 90 days of treatment with dimethoate [35]. Vacuolation, germ cell depletion and germ cell sloughing (exfoliation) were, in a like manner, found in experiments conducted by two separate researchers in which chlorpyrifos, another organophosphate, was given for periods of 45 and 90 days respectively [36,37]. A combination of chlorpyrifos and fenitrothion administered for 28 days produced necrosis and tubular atrophy in one study [38]. There were few histological

changes recorded by these studies unlike this present work which explicitly presented histological changes not previously documented in any similar research. In addition, this work further scored the histological findings on a semi-quantitative scale to compare the severity of observed changes.

This work also uniquely correlated the frequency of the histological changes with measured blood hormones. After 50 weeks of dichlorvos administration, there was no statistically significant correlation between DHT, FSH, and LH with the frequencies of histological alterations. There was a strong positive correlation between both germ cell exfoliation and residual bodies, and progesterone. Oestrogen also correlated with germ cell exfoliation, depletion and presence of residual bodies. Germ cell degeneration is the end point of most toxicants [39]. The correlation between the hormone levels and histological changes appear unpredictable in this study. Certainly, male sub-fertility observed in pesticide exposure may not be simplistically explained by hormone disruption or direct cytotoxicity alone. Perhaps, these factors and more subtle molecular and genetic pathways are involved.

A paper which reviewed findings from various human and animal studies to determine the risk of breast cancer on dichlorvos exposure concluded that there was lack of express evidence of its carcinogenicity [40]. And a previous seminal research conducted by Chan et al. [41] in which dichlorvos was given for 103 weeks failed to find any neoplasm in the reproductive organs of the male rats and mice [41]. Similarly, in the present study in which the rats were exposed to dichlorvos for 50 weeks, there was no neoplastic growth found in the testes of any of the animals. However, a large cohort study disclosed that there exist a little excess risk of prostate cancer from lifetime exposure to dichlorvos [42].

5. CONCLUSION

This research evaluated the chronic effect of low dichlorvos exposure on reproductive function using an animal model. Firstly, variation in the exposure dose had significant effects on blood levels of FSH. Secondly, prolonged exposure failed to influence the blood levels of luteinizing hormone in the animals. Thirdly, most of the animals experienced tubular atrophy or degeneration. Fourthly, the correlations between

the hormones and histological changes were largely unpredictable. There was a strong positive correlation between progesterone and germ cell exfoliation and residual bodies. Oestrogen also correlated with germ cell exfoliation, depletion and presence of residual bodies. This is probably due to the complex molecular pathways and their interactions to induce metabolic or hormone disruption, cytotoxicity and genotoxicity caused by dichlorvos.

CONSENT

It is not applicable.

ETHICAL APPROVAL

Ethical clearance for this research was obtained from the research ethics committee of the University of Jos (Protocol date: 4th September 2018, Reference Number: F17-00379). The recommendations from the Declaration of Helsinki and the Guiding Principles in the Care and Use of Animals for Experimentation were followed in the course of this research.

COMPETING INTERESTS

Authors have declared that no competing interests exist.

REFERENCES

1. Holdcraft RW, Braun RE. Hormonal regulation of spermatogenesis. *Int J Androl.* 2004;27(6):335–42.
2. Babu SR, Sadhnani MD, Swarna M, Padmavathi P, Reddy PP. Evaluation of FSH, LH and testosterone levels in different subgroups of infertile males. *Indian J Clin Biochem.* 2004;19(1):45–9.
3. Sengupta P, Banerjee R. Environmental toxins: Alarming impacts of pesticides on male fertility. *Hum Exp Toxicol.* 2014; 33(10):1017–39.
4. Latini G, Knipp G, Mantovani A, Marcovecchio ML, Chiarelli F, Söder O. *Endocrine Disruptors and Human Health.* 2010;(October 2015).
5. Mnif W, Hassine AIH, Bouaziz A, Bartegi A, Thomas O, Roig B. Effect of endocrine disruptor pesticides: A Review. *Int J Environ Res Public Health.* 2011;8(6): 2265–303.
6. Bond GG, Dietrich DR. Human cost burden of exposure to endocrine disrupting

- chemicals. A critical review. *Arch. Toxicol.* 2017;91(8):2745–62.
7. Tomer V, Sangha JK, Ramya HG. Pesticide: An appraisal on human health implications. *Proc Natl Acad Sci India Sect B Biol Sci.* 2015;85(2):451–63.
 8. Quality D. Dichlorvos in Drinking-water.
 9. Sinyangwe DM, Mbewe B, Sijumbila G. Determination of dichlorvos residue levels in vegetables sold in Lusaka, Zambia. *Pan Afr Med J.* 2016;23:1–7.
 10. Gwary OM, Hati SS, Dimari GA, Ogugbuaja VO. pesticide residues in bean samples from Northeastern Nigeria. *ARNP J Sci Technol*; 2012.
 11. Creasy D, Bube A, Rijk E de, Kandori H, Kuwahara M, Masson R, et al. Proliferative and nonproliferative lesions of the rat and mouse male reproductive system. *Toxicol Pathol.* 2012;40(6_suppl):40S-121S.
 12. Lanning LL, Creasy DM, Chapin RE, Mann PC, Barlow NJ, Regan KS, et al. Recommended approaches for the evaluation of testicular and epididymal toxicity. *Toxicol Pathol.* 2002;30(4):507–20.
 13. Oduwole OO, Peltoketo H, Huhtaniemi IT. Role of follicle-stimulating hormone in spermatogenesis. *Front Endocrinol (Lausanne).* 2018;9(December):1–11.
 14. Dirican EK, Kalender Y. Dichlorvos-induced testicular toxicity in male rats and the protective role of vitamins C and E. *Exp Toxicol Pathol.* 2012;64(7–8):821–30.
 15. Krause W. Influence of DDT, DDVP and malathion on FSH, LH and testosterone serum levels and testosterone concentration in testis. *Bull Environ Contam Toxicol.* 1977;18(2):231–42.
 16. Sharma B, Sharma P, Joshi SC. Mitigating effects of zingiber officinale against reproductive toxicity induced by dichlorvos in male rats. *Int J Pharm Pharm Sci.* 2017;9(5):107–13.
 17. Abdallah MS, Saad-hussein A, Shahy EM, Seleem M, Abdel-aleem AM. Effects of occupational exposure to pesticides on male sex hormones. *J Biosci Appl Res.* 2017;3(3):70–9.
 18. Slimani S, Boulakoud MS, Abdennour C. Pesticide exposure and reproductive biomarkers among male farmers from north-east Algeria. *Ann Biol Res.* 2011; 2(2):290–7.
 19. Bui-Nguyen TM, Baer CE, Lewis JA, Yang D, Lein PJ, Jackson DA. Dichlorvos exposure results in large scale disruption of energy metabolism in the liver of the zebrafish, *Danio rerio*. *BMC Genomics.* 2015;16(1):1–18.
 20. Romero-Navarro G, Lopez-Aceves T, Rojas-Ochoa A, Fernandez Mejia C. Effect of dichlorvos on hepatic and pancreatic glucokinase activity and gene expression, and on insulin mRNA levels. *Life Sci*; 2006.
 21. Sorenson RL, Stout LE, Breje TC, Jetton TL, Matschinsky FM. Immunohistochemical evidence for the presence of glucokinase in the gonadotropes and thyrotropes of the anterior pituitary gland of rat and monkey. *J Histochem Cytochem.* 2007;55(6):555–66.
 22. Karami-Mohajeri S, Abdollahi M. Toxic influence of organophosphate, carbamate, and organochlorine pesticides on cellular metabolism of lipids, proteins, and carbohydrates. *Hum Exp Toxicol.* 2011; 30(9):1119–40.
 23. Scott V, Brown CH. Beyond the GnRH Axis: Kisspeptin Signaling in Reproductive Biology. 2013;784:201–18.
 24. Moore AM, Coolen LM, Lehman MN. Kisspeptin/Neurokinin B/Dynorphin (KNDy) cells as integrators of diverse internal and external cues: Evidence from viral-based monosynaptic tract-tracing in mice. *Sci Rep.* 2019;9(1):26–8.
 25. Stojilkovic SS. Pituitary cell type-specific electrical activity, calcium signaling and secretion. *Biol Res.* 2006;39(3):403–23.
 26. Stojilkovic SS, Bjelobaba I, Zemkova H. Ion channels of pituitary gonadotrophs and their roles in signaling and secretion. *Front Endocrinol (Lausanne).* 2017;8(JUN):1–9.
 27. Matschinsky FM, Wilson DF. The Central role of glucokinase in glucose homeostasis: A perspective 50 years after demonstrating the presence of the enzyme in islets of langerhans. *Front Physiol.* 2019;10(MAR).
 28. Okamura A, Kamijima M, Shibata E, Ohtani K, Takagi K, Ueyama J, et al. A comprehensive evaluation of the testicular toxicity of dichlorvos in Wistar rats. *Toxicology.* 2005;213(1–2):129–37.
 29. Binukumar BK, Bal A, Gill KD. Chronic Dichlorvos Exposure: Microglial Activation, Proinflammatory Cytokines and Damage to Nigrostriatal Dopaminergic System. *NeuroMolecular Med.* 2011;13(4):251–65.
 30. DSouza U. Pesticide toxicity and oxidative stress: A Review. *Borneo J Med Sci.* 2017;11(2):9–19.

31. Nazam N, Iqbal Lone M, Shaikh S, Ahmad W. Assessment of genotoxic potential of the insecticide Dichlorvos using cytogenetic assay. *Interdiscip Toxicol.* 2013;6(2):77–82.
32. Ruwanpura SM, Mclachlan RI, Meachem SJ. Hormonal regulation of male germ cell development; 1998.
33. El-Gerbed MSA. Histopathological and ultrastructural effects of methyl parathion on rat testis and protection by selenium. *J Appl Pharm Sci.* 2013;3(8 SUPPL):53–63.
34. Brilhante O, Okada FK, Sasso-Cerri E, Stumpp T, Miraglia SM. Late morfofunctional alterations of the Sertoli cell caused by doxorubicin administered to prepubertal rats. *Reprod Biol Endocrinol.* 2012;10:79.
35. Ngoula F. Effect of dimethoate (an organophosphate insecticide) on the reproductive system and fertility of adult male rat. *Am J Pharmacol Toxicol.* 2014; 9(1):75–83.
36. Babazadeh M, Najafi G. Effect of chlorpyrifos on sperm characteristics and testicular tissue changes in adult male rats. 2017;8(4):319–26.
37. Kenfack A, Ngoula F, Dzeufiet PDW, Ngouateu OB, Martine TMA, Chombong JK, et al. Persistence of the reproductive toxicity of chlorpyrifos-ethyl in male Wistar rat. *Asian Pacific J Reprod.* 2015; 4(1):37–40.
38. Gawish AM. The Protective Role of Alpha Lipoic Acid Against pesticides Induced Testicular Toxicity- Histopathological and Histochemical Studies. 2010;1(1):1–7.
39. Murphy CJ, Richburg JH. Implications of Sertoli cell induced germ cell apoptosis to testicular pathology. *Spermatogenesis.* 2014;4(2):e979110.
40. Gandhi R, Snedeker SM. Critical evaluation of dichlorvos' breast cancer risk. *Comments Toxicol.* 2002;8(1):85–123.
41. Chan PC, Huff J, Haseman JK, Alison R, Prejean JD. Carcinogenesis studies of dichlorvos in fischer rats and B6C3F1 Mice. *Japanese J Cancer Res* 1991;82(2): 157–64.
42. Lerro CC, Koutros S, Andreotti G, Friesen MC, Alavanja MC, Blair A, et al. Organophosphate insecticide use and cancer incidence among spouses of pesticide applicators in the Agricultural Health Study. *Occup Environ Med.* 2015; 72(10):736–44.

© 2020 Vhritherhire et al.; This is an Open Access article distributed under the terms of the Creative Commons Attribution License (<http://creativecommons.org/licenses/by/4.0>), which permits unrestricted use, distribution, and reproduction in any medium, provided the original work is properly cited.

Peer-review history:
The peer review history for this paper can be accessed here:
<http://www.sdiarticle4.com/review-history/57400>