

Case Report

**Familial Adenomatous Polyposis (FAP): a case study in the eastern Democratic Republic of the Congo**

**Authors:** \*Kahatwa Kiringa Serge MD<sup>1</sup>, Megan Zalzal<sup>2</sup>, Kahatwa Bahizi Edouard MD<sup>3</sup>, Mumbere Hangi Stan MD<sup>4</sup>, Kasereka Kihemba MD<sup>5</sup> Susan A. Bartels MD, MPH, FRCPC<sup>6</sup>.

1. Kahatwa K. Serge MD, Department of Internal Medicine, University of Goma, HEAL Africa hospital, Goma, DR Congo.
2. Megan Zalzal, student, medical school, Queens University, Kingston, Canada
3. Kahatwa B. Edouard MD, Department of Surgery, Catholic University la Sapiencia, Goma, DR Congo
4. Mumbere Hangi Stan MD, department of pediatrics University of Goma, HEAL Africa hospital, Goma, DR Congo.
5. Kasereka kihemba MD, Department of histopathology University of Goma, HEAL Africa hospital, Goma, DR Congo.
6. Susan A. Bartels, Departments of Emergency Medicine and Public Health Sciences, Queen's University, Kingston, Canada.

\*Corresponding author: Kahatwa Kiringa Serge MD, serge\_luc@yahoo.fr, +243971823993.

DOI: [10.21608/ajgh.2022.120465.1003](https://doi.org/10.21608/ajgh.2022.120465.1003)

Submission date: 11- February- 2022.

Reviewers began the manuscript. revision : 11- February- 2022.

Revision completed and sent to the authors: 02- March- 2022.

The authors submitted the revised manuscript: 27- April- 2022.

First online: 06- May-2022.

---

**Abstract*****Background***

FAP is an inherited disorder caused by the adenomatous polyposis coli (APC) gene mutation. Left untreated, the risk of developing colon cancer approaches 100%. Unfortunately, there is a lack of literature regarding FAP in Sub-Saharan Africa. Therefore, it is difficult to determine the disease burden in this region. Consequently, it is essential to publish case reports, such as this one, to promote further research to understand the epidemiology of FAP in this part of the world.

***Aim***

To report a case of familial adenomatous polyposis (FAP) in a boy whose symptoms started at 12 in the Democratic Republic of Congo (DR Congo).

***Patients and Methods***

A 12-year-old male resident of Goma, from the Nande tribe in North Kivu, DR Congo, presented to the hospital with a two-year history of recurrent abdominal pain and diarrhea associated with blood-tinged stools and occasional episodes of bright red rectal bleeding. Further history, clinical exam, laboratory tests, and colonoscopy demonstrated findings consistent with FAP. A total colectomy was eventually performed, followed by an ileorectal anastomosis.

***Results***

A good outcome was achieved with retained anal sensation and good fecal continence. However, the patient did experience loose stools with occasional nocturnal fecal incontinence.

***Conclusion***

This case report confirms the presence of FAP in Sub-Saharan Africa and eastern DR Congo. However, more research is needed to understand the incidence and prevalence of FAP better and guide the development of screening and treatment programs for this condition.

***Keywords:*** Familial adenomatous polyposis, colon cancer, case report, Sub-Saharan Africa, Democratic Republic of Congo.

---

## Introduction

Familial adenomatous polyposis (FAP) is an inherited disorder characterized by hundreds to thousands of polyps in the digestive tract. It is an autosomal dominant disorder resulting from the adenomatous polyposis coli (APC) gene mutation. Located on chromosome 5q21, mutation of the tumor-suppressing APC gene can lead to its inactivation. Three specific locations of transformation in the APC gene have been identified: exon 9, the proximal (5') end of the APC gene, and the distal (3') end of the APC gene. The number of polyps a patient has can be indicated by gene mutation location [1]. Evidence suggests a genetic predisposition for some colorectal tumors [2], and some families' risk of transition from a benign mass to carcinoma increases. With FAP, the transformation of benign polyps into carcinomas typically occurs before the age of 40[3, 4].

Early diagnosis and treatment of FAP can prevent or reduce this risk of malignant transformation and improve the survival of those predisposed and affected [5, 6]. Although an increased prevalence of FAP has been demonstrated within specific communities, very few cases have been reported in Africa, especially in its Sub-Saharan areas [7].

Clinical confirmation of FAP is rare in Sub-Saharan Africa and DR Congo, suggesting a very low recognized incidence of this disorder. We present a case study of a FAP detected and treated in eastern DR Congo to raise awareness about this disease.

## Case presentation

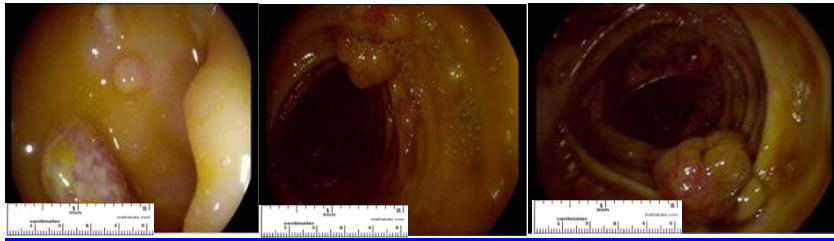
A 12-year-old male resident of Goma, of the Nande tribe in North Kivu, DR Congo, presented with recurrent abdominal pain and diarrhea associated with blood-tinged stools and occasional episodes of bright red rectal bleeding. These symptoms were associated with occasional anorexia and mild weight loss.

Family history indicated that the patient's biological mother had died of colon cancer. Her initial presentation was similar to her son's; however, she was treated for several years for a suspected intestinal parasitosis. Persistent symptoms of abdominal bloating and recurrent constipation had prompted abdominal ultrasound imaging for the mother, which had revealed an abdominal mass. Based on this finding, she underwent exploratory laparotomy with biopsy, which confirmed the diagnosis of colon cancer. She was treated with surgical excision of the tumor, colostomy, and chemotherapy but died within one year of diagnosis.

The boy's physical examination was otherwise unremarkable, revealing a healthy adolescent with no visible skin lesions.

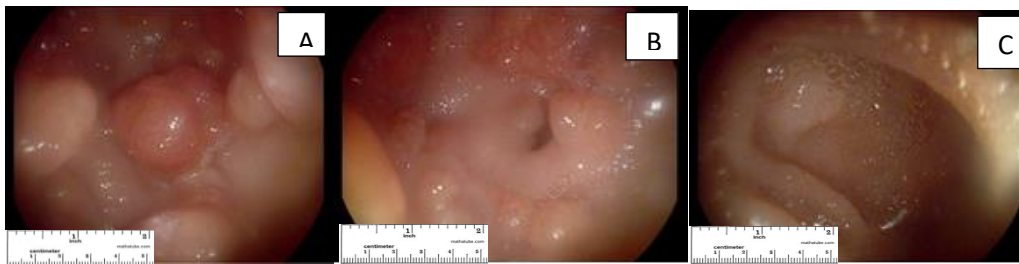
Laboratory investigation ruled out malaria but revealed moderate anemia.

The patient received empirical treatment with anthelmintics, antibiotics, antimalarials, and anti-inflammatory drugs and received treatment for chronic anemia. A manual rectal examination and colonoscopy were performed when he failed to improve clinically. A manual rectal examination revealed several smooth masses of firm consistency. Colonoscopy demonstrated several polyps of varying size, with some polyps between the rectum and the cecum showing signs of inflammation or budding (Fig 1).



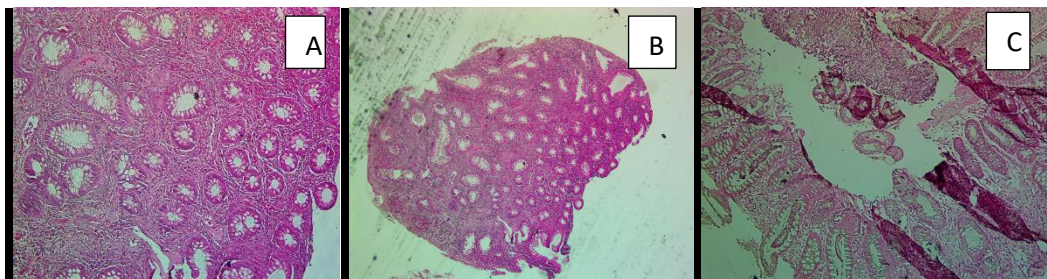
*Fig 1 :Colonoscopy images*

Based on the colonoscopy results, an esophagogastroduodenoscopy was performed. This identified several gastric polyps of various sizes. In addition, the esophagus and duodenum were normal in appearance (Fig 2).



*Fig 2: Esophagogastroduodenoscopic images : A- Gastric cavity, B- Antrum and pylorus, C- Duodenal bulb*

Biopsies of polyps were done with pathology examinations that confirmed the polyps' adenomatous characteristics. (Fig 3)



*Fig 3: histological pictures of polyp biopsies : A: Transverse colon, Objective x 10H&E, B: Sigmoid colon, Objective x4H&E, C: Rectum, Objective x 10H&E.*

#### **Pathology report of the colon polyps**

Microscopically, there is an increase in the number of glands and cells per unit area compared to the normal mucosa. In addition, the cells are crowded, contain enlarged hyperchromatic nuclei, and have an increased number of mitoses.

Based on history, physical examination, investigations, and biopsy results, it was concluded that this represented a case of FAP. To the best of our knowledge, this was the first case of FAP in a 12-year-old male adolescent of Congolese nationality from the Nande tribe in Goma.

---

Although the diagnosis of the patient's mother was never confirmed, it is suspected that the 12-year-old boy likely inherited the FAP gene from his mother.

### **Treatment**

Based on the child's age and clinical findings, it was decided that the patient should undergo a total colectomy and annual monitoring to detect malignant transformation. One year later, at the age of 13 and with informed consent from the patient and his father, the patient underwent a total colectomy with the placement of a permanent jejunostomy. During surgery, the presence of polyps in the terminal ileum was identified. Repeated biopsy confirmed FAP, and no malignancy was detected.

Two months after total colectomy, the ileostomy was closed, and an ileorectal anastomosis was performed. Again, the patient experienced a good outcome with retained anal sensation and good fecal continence. He did, however, experience loose stools with occasional nocturnal fecal incontinence.

### **Discussion**

The occurrence of FAP and colorectal cancer have been underreported in Sub-Saharan Africa. However, one case study presented by Alese et al. reported a 70-year-old woman with clinical symptoms and radiological findings of FAP [7]. The lack of literature on FAP in Sub-Saharan Africa is likely due to the lack of screening tools and diagnostic procedures available in the region. For example, endoscopes for colonoscopy and antigenic and inflammatory testing are not as readily available in other parts of the world.

Our patient inherited FAP from his mother since it is an autosomal dominant disorder and the mother's clinical records indicated that she died of colon cancer. Unfortunately, no clinical records were available for any previous generations to determine the family origin of FAP in this lineage.

The average age of symptom onset among patients with FAP is between 16 and 35 years and possibly earlier in the case of the florid polyposis linked to the APC gene. Endoscopic surveillance can usually be started around 11, but close monitoring in families carrying the gene is generally recommended at 10 to 12 years [4, 8, 9]. In the case presented here, signs and symptoms began around age 10. This is early compared to what has been reported elsewhere in the literature. For example, a study presented by Petersen et al. showed that the clinical signs of polyposis often appear around 34 in family members with the APC gene [8].

The patient complained of recurrent abdominal pain associated with diarrhea, occasional blood-tinged stools, and episodes of rectal bleeding. According to *Bennefoy et al.*, symptoms that require investigation by colonoscopy include rectal bleeding, occult blood in stools, recurrent abdominal pain, and even chronic diarrhea [10]. Concerning the pediatric population, *Dabadie, Bellaiche, et al.* described indications for colonoscopy in children, including unexplained iron deficiency anemia, digestive symptoms, and rectal bleeding, amongst others [11]. Rectal bleeding and motility disorders were also reported as symptoms of FAP by Tijani et al. in 2008 [12].

---

The esophagogastroduodenoscopy, in this case, demonstrated gastric polyposis. However, the esophagus and the duodenum looked healthy, with no polyps identified. This is in keeping with reports from the literature. For example, Church et al. found that 66% of FAP cases also showed gastric polyps. However, 61% had polyps in the duodenum in their study, whereas the patient presented here did not [13].

Genetic testing is helpful for the detection of FAP and colorectal cancer, with a screening of family members often recommended for definitive diagnosis [14]. The APC gene responsible for FAP was isolated in 1991 [15]. However, in Sub-Saharan Africa, it is often challenging to obtain genetic testing. Therefore, it was not performed for the patient discussed in this case study. The diagnosis, however, was made based on history, clinical examination, suspected family history, laboratory testing, and gastrointestinal tract scoping.

In the case presented, a total colectomy with the placement of a jejunostomy was performed. This was followed by an ileorectal anastomosis two months later. The treatment plan was reported in the literature by *Tijani et al.* at the Ibn Sina Hospital in Rabat, where both ileoanal and ileorectal anastomoses were described [12]. Total colectomy at age 13 may appear to be an aggressive treatment. However, the risk of malignant transformation to colorectal cancer approaches 100% in FAP. There is no management consensus in the literature; in Anglo-Saxon countries, surgical intervention is recommended between 20 and 30, while performed at younger ages in other parts of Europe. Advocates of earlier surgical intervention rationalized this approach based on the risk of developing colorectal cancer [14]. In this case, the family discussion revealed financial stress and concerns regarding prompt access to healthcare, contributing factors to management decisions. The surgical intervention was justified by the high risk of malignant transformation, lack of curative medical management, and family wishes.

The ileorectal anastomosis was performed because of the patient's young age and the anticipated improved quality of life it would provide compared to living long-term with a colostomy. Furthermore, it was determined that the patient was sufficiently educated and compliant, with enough family support to maximize the chances of a positive outcome for the surgical procedure.

### Conclusion

FAP is presumed to be rare in Sub-Saharan Africa. However, this case report does confirm the existence of FAP in the region, and we wish to raise awareness about the diagnosis. Determining the exact prevalence and incidence is difficult due to the lack of available genetic testing and diagnostic tools. Additional research is needed to understand further the burden of FAP in Sub-Saharan Africa and neighboring regions.

### Acronyms

|          |                                 |
|----------|---------------------------------|
| APC      | Adenomatous polyposis coli.     |
| DR Congo | Democratic Republic of Congo.   |
| FAP      | Familial adenomatous polyposis. |

---

## Footnotes.

**Peer- Reviewers:** Emad F Hamed (professor of internal medicine), Hayam Rashed (professor of pathology), Samia Hussein (assistant professor of biochemistry), Marwa Shabana (lecturer of clinical pathology), Adenylza Paiva.

**E- Editor:** Salem Y Mohamed, Emad Fawzi Hamed.

**This work was done according to the CARE guidelines.**

**Copyright ©.** This open-access article is distributed under the [Creative Commons Attribution License \(CC BY\)](#). The use, distribution, or reproduction in other forums is permitted, provided the original author(s) and the copyright owner(s) are credited. The original publication in this journal is cited by accepted academic practice. No use, distribution, or reproduction is permitted, complying with these terms.

**Disclaimer:** All claims expressed in this article are solely those of the authors and do not necessarily represent their affiliated organizations or those of the publisher, the editors, and the reviewers. Any product evaluated in this article or claim that its manufacturer may make is not guaranteed or endorsed by the publisher.

## Funding

This research did not receive any specific grant from funding agencies in the public, commercial, or not-for-profit sectors.

## Declaration of competing interest

There are no conflicts of interest related to this study.

## Acknowledgments

---

**References**

1. Sokic-Milutinovic, A. (2019). Appropriate Management of Attenuated Familial Adenomatous Polyposis: Report of a Case and Review of the Literature. *Digestive diseases (Basel, Switzerland)*, 37(5), 400–405. <https://doi.org/10.1159/000497207>
2. Bonaiti-Pellié, C., Eisinger, F., Feingold, J. et al. (2005). [Hereditary predispositions to colorectal cancer]. *Gastroenterol Clin Biol*, 29(6-7), 701-710. [https://doi.org/10.1016/s0399-8320\(05\)82159-1](https://doi.org/10.1016/s0399-8320(05)82159-1) (Prédispositions héréditaires au cancer colorectal.)
3. Galiatsatos, P., & Foulkes, W. D. (2006). Familial adenomatous polyposis. *Am J Gastroenterol*, 101(2), 385-398. <https://doi.org/10.1111/j.1572-0241.2006.00375.x>
4. Knudsen, A. L., Bisgaard, M. L., & Bulow, S. (2003). Attenuated familial adenomatous polyposis (AFAP). A review of the literature. *Fam Cancer*, 2(1), 43-55. <https://doi.org/10.1023/a:1023286520725>
5. Winawer, S. J., John, D. J. S., Bond, J. H. et al. (1995). Prévention du cancer colorectal: mise à jour des directives. *Bulletin of the World Health Organization*, 73(2), 137-141. <https://www.ncbi.nlm.nih.gov/pmc/articles/PMC2486748/>
6. Roland, S.C, Wolfgang, M, B , Bertram R, et al. (2005). Age and manifestation-related symptoms in familial adenomatous polyposis. *BMC Cancer* 2005, 5:24 doi:10.1186/1471-2407-5-24. : <http://www.biomedcentral.com/1471-2407/5/24>
7. Alese, O. B., & Irabor, D. O. (2009). Adenomatous polyposis coli in an elderly female Nigerian. *Ghana Med J*, 43(3), 139-141. <https://doi.org/10.4314/gmj.v43i3.55341>
8. Petersen, G. M., Slack, J., & Nakamura, Y. (1991). Screening guidelines and premorbid diagnosis of familial adenomatous polyposis using linkage. *Gastroenterology*, 100(6), 1658-1664. [https://doi.org/10.1016/0016-5085\(91\)90666-9](https://doi.org/10.1016/0016-5085(91)90666-9)
9. Koskenvuo, L., Renkonen-Sinisalo, L., Järvinen, H. J., & Lepistö, A. (2014). Risk of cancer and secondary proctectomy after colectomy and ileorectal anastomosis in familial adenomatous polyposis. *Int J Colorectal Dis*, 29(2), 225-230. <https://doi.org/10.1007/s00384-013-1796-4>
10. Bonnefoy, S., Béchade, D., Bertocchi, C., Blondon, H., Desramé, J., & Algayres, J. P. (2009). [Sporadic colonic juvenile polyps in adults]. *Gastroenterol Clin Biol*, 33(1 Pt 1), 88-91. <https://doi.org/10.1016/j.gcb.2008.05.009> (Polypes coliques juvéniles sporadiques de l'adulte.)
11. Dabadie, A., Bellaiche, M., Cardey, J., Lachaux, A., Michaud, L., & Morali, A. (2012). [Current indications of ileocolonoscopy in children in 2012]. *Arch Pediatr*, 19(11), 1247-1251. <https://doi.org/10.1016/j.arcped.2012.08.005> (Mise au point : évolution des indications de la coloscopie chez l'enfant en 2012.)
12. Tijani, I. (2008). Résultats du traitement chirurgical de la polypose adénomateuse familiale (expérience de la clinique chirurgicale " A").
13. Church, J. M., McGannon, E., Hull-Boiner, S. et al. (1992). Gastroduodenal polyps in patients with familial adenomatous polyposis. *Dis Colon Rectum*, 35(12), 1170-1173. <https://doi.org/10.1007/bf02251971>
14. Roy, H. K., & Khandekar, J. D. (2012). APC Gene Testing for Familial Adenomatous Polyposis. *JAMA*, 308(5), 514-515. <https://doi.org/10.1001/jama.2012.9516>
15. Groden, J., Thliveris, A., Samowitz, W. et al. (1991). Identification and characterization of the familial adenomatous polyposis coli gene. *Cell*, 66(3), 589-600. [https://doi.org/10.1016/0092-8674\(81\)90021-0](https://doi.org/10.1016/0092-8674(81)90021-0)
16. Bretagnol, F., & Rault, A. (2013). Chirurgie colorectale prophylactique. *La Lettre de l'hépatogastroentérologue*, 16(5).