



## Recoverability of renal function after relief of chronic partial unilateral ureteric obstruction: The effect of an angiotensin-converting enzyme inhibitor (enalapril)

Shady A. Soliman, Ahmed A. Shokeir, Ahmed Mosbah, Hassan Abol-Enein, Nashwa Barakat, Essam Abou-Bieh & Ehab W. Wafa

To cite this article: Shady A. Soliman, Ahmed A. Shokeir, Ahmed Mosbah, Hassan Abol-Enein, Nashwa Barakat, Essam Abou-Bieh & Ehab W. Wafa (2011) Recoverability of renal function after relief of chronic partial unilateral ureteric obstruction: The effect of an angiotensin-converting enzyme inhibitor (enalapril), Arab Journal of Urology, 9:1, 67-71, DOI: [10.1016/j.aju.2011.03.016](https://doi.org/10.1016/j.aju.2011.03.016)

To link to this article: <https://doi.org/10.1016/j.aju.2011.03.016>



© 2011 Arab Association of Urology



Published online: 05 Apr 2019.



Submit your article to this journal [↗](#)



Article views: 269



View related articles [↗](#)



Citing articles: 1 View citing articles [↗](#)



**Arab Journal of Urology**  
(Official Journal of the Arab Association of Urology)

www.sciencedirect.com



ORIGINAL ARTICLE

# Recoverability of renal function after relief of chronic partial unilateral ureteric obstruction: The effect of an angiotensin-converting enzyme inhibitor (enalapril)

Shady A. Soliman, Ahmed A. Shokeir \*, Ahmed Mosbah, Hassan Abol-Enein, Nashwa Barakat, Essam Abou-Bieh, Ehab W. Wafa

Urology & Nephrology Center, Mansoura University, Mansoura, Egypt

Received 23 February 2011, Accepted 16 March 2011

Available online 6 May 2011

**KEYWORDS**

Ureteric obstruction;  
Recoverability of renal  
function;  
Enalapril

**ABBREVIATIONS**

(U)UO, (unilateral) ureteric  
obstruction; ACE,  
angiotensin-converting  
enzyme; RAS, renin-  
angiotensin system; CCr,  
creatinine clearance; DUS,  
Doppler  
ultrasonography; RI,  
resistive index; RCr,  
renographic clearance

**Abstract Objectives:** We evaluated the effect of an angiotensin-converting enzyme inhibitor (enalapril) on renal function during and after the relief of partial unilateral ureteric obstruction (UUO).

**Materials and methods:** Thirty-two male mongrel dogs were classified into three groups: sham (eight), control (12; left partial UUO + no medication) and study (12; left partial UUO + enalapril). Dogs in the study and control groups were subjected to 4 weeks of partial UUO. After that, the dogs were re-opened and subjected to Lich-Gregoir vesico-ureteric re-implantation, and were killed humanely by the end of the eighth week after relief of obstruction. The study and control groups were evaluated at baseline, after 4 weeks of obstruction and at 4 and 8 weeks after relief of obstruction, by measuring selective creatinine clearance (CCr), selective renographic clearance (RCr) and renal resistive index (RI). The sham group had sham surgery at 4 and 8 weeks and was evaluated as the other two groups.

**Results:** Sham surgery showed no significant effect on any of the evaluated variables. Compared with the control, enalapril offset the reductions of CCr and RCr by an extra 11% and 12% of the basal values by the end of the fourth week of obstruction, respectively. Moreover, compared with the control, enalapril enhanced the recovery of CCr by an extra 10% and of RCr by an extra 23% of the basal values at 8 weeks after relief of the 4-week obstruction. In addition, the increase in RI was significantly less in the enalapril group.

**Conclusion:** Enalapril decreases the deterioration of renal function in partial UUO and enhances the recoverability of renal function after relief of obstruction.

© 2011 Arab Association of Urology. Production and hosting by Elsevier B.V. All rights reserved.

\* Corresponding author. Tel.: +20502262222; fax: +20502263717.  
E-mail address: [ahmed.shokeir@hotmail.com](mailto:ahmed.shokeir@hotmail.com) (A.A. Shokeir).



## Introduction

Obstructive uropathy is of great importance to clinicians because it is a common entity in all ages that is treatable and often reversible. Several integrating cellular and molecular events that soon prevail after ureteric obstruction (UO) ultimately lead to loss of renal function [1]. Renal cellular and structural changes in obstructive renal injury depend on the interaction between many mediators, including angiotensin II, TGF- $\beta$ , nuclear factor  $\kappa$ -B, TNF- $\alpha$  and endothelin [2].

Angiotensin II, a potent vasoconstrictor, is produced following conversion of angiotensinogen into angiotensin I by the enzyme renin and subsequently, conversion of angiotensin I into angiotensin II by angiotensin-converting enzyme (ACE). Angiotensin II production is rapidly stimulated following the onset of renal obstruction and has been linked to many of the pathophysiological processes involved in renal obstruction, including alterations in renal haemodynamics, fibrosis and apoptosis [3]. The renin-angiotensin system (RAS) has been shown to have a significant role in the progression of virtually all renal disorders, and pharmacological inhibition of angiotensin II is a widely accepted therapy for attenuating or preventing renal deterioration. As urinary tract obstruction itself markedly activates the RAS, the rationale for angiotensin II inhibition in this setting would seem to be particularly strong [4].

Enalapril is an effective, orally active, ACE inhibitor. In unilateral UO (UUO), angiotensin II blockade with enalapril markedly diminished tubular lesions and inflammatory cell infiltration [5], reduced the monocellular infiltration of the kidney by monocytes/macrophages [6], and decreased fibrosis, apoptosis and TGF- $\beta$  expression in the obstructed kidney [7].

The beneficial reno-protective effect of enalapril was explored during the obstruction phase of complete UUO [5–11]. To the best of our knowledge, the reno-protective effect of enalapril during and after relief of chronic partial UUO has never been explored.

The present study comprised a controlled experiment to evaluate the effect of enalapril on decreasing the deterioration of renal function in partial UUO; the effect of enalapril on the improvement of recoverability of renal function after relief of UO was investigated in a canine model.

## Materials and methods

Thirty-two male mongrel dogs (aged 2–3 years, 18–25 kg) were used; eight dogs were designated as a sham group and underwent abdominal exploration. The bladder was opened, a 6 F ureteric catheter was inserted into the left ureteric orifice for 2 h to collect urine samples and a blood sample was taken from the left renal vein. The catheter was then removed and the bladder and wound were closed without induction of left UO.

In the remaining 24 dogs, left partial UO was created as previously described [12]. A 6 F ureteric catheter was inserted into the left ureteric orifice, and was cut 2 cm distal to the orifice and fixed into the bladder mucosa. The most distal part of the ureter was ligated around the catheter. The stylet of the 6 F ureteric catheter was inserted inside the lumen of the catheter, thus inducing a severe form of partial UO [12]. The procedures

were carried out under general anesthesia using thiopental sodium (10 mg/kg) with endotracheal intubation and mechanical ventilation.

The dogs were classified into three groups: a sham group (eight dogs; sham surgery + no medication), a control group (12 dogs; left partial UO + no medication); and a (study) enalapril group (12 dogs; left partial UO + enalapril). Dogs in the last group were given enalapril at 0.5 mg/kg/day once daily in the drinking water (after overnight fasting of dogs) for the duration of the study [13].

Dogs in the sham group had to sham surgery at baseline, 4 and 8 weeks, and were killed humanely thereafter. The enalapril and control groups had 4 weeks of left partial UO, and were then re-opened and subjected to Lich-Grigoir vesico-ureteric re-implantation. By the end of the eighth week after relief of obstruction, all dogs of the control and enalapril groups were explored and the left kidney was harvested. The dogs were killed at the end of the eighth week after relief of obstruction. The study was approved by the local ethical committee.

For the control and enalapril groups the evaluation included an estimation of selective endogenous creatinine clearance (CCr) through blood and urine samples collected from the corresponding kidney during surgery just before the induction of obstruction, during relief of obstruction (at 4 weeks of obstruction) and at death at the end of the 8th week after relief of obstruction. Two urine samples were collected, each for 2 h, from the corresponding ureter (the mean volume of urine produced for 2 h was multiplied by 12 to estimate the urine volume for 24 h), and blood samples obtained from the corresponding renal vein. Blood samples and the mean of two readings of urine samples were used to calculate the CCr from the equation of Edelstein and Cronin [14], as (urine creatinine, mg/dL,  $\times$  urine volume, mL/24 h)/(serum creatinine, mg/dL  $\times$  1440 min).

The evaluation also included Doppler ultrasonography (DUS) with a measurement of renal resistive index (RI) of the corresponding kidney, and radioisotope renography, with calculation of the split function of the corresponding kidney. DUS and renography were carried out, as previously described [15], at baseline before inducing obstruction, just before the relief of obstruction (after 4 weeks of obstruction) and at 4 and 8 weeks after relief of obstruction. Briefly, diuretic renography was conducted according to a standard protocol for all dogs. In each dog a urethral catheter was placed and normal saline was given intravenously (1 mL/kg/min for 15 min). The dog was placed supine on the scanning table and  $^{99m}\text{Tc}$ -MAG3 was injected intravenously in a dose of 2.1 MBq/kg, and a standard renal scan performed. After 20 min, 1 mg/kg furosemide was injected intravenously [15].

DUS was done by one expert radiologist. After being sedated, the dogs were given intravenous normal saline (1 mL/kg/min, 5 min) before Doppler studies and a urethral catheter was inserted. Infusion of normal saline to replace urine output was continued during the entire course of Doppler studies. DUS was conducted using the Voluson 730 Expert (GE Medical Systems, Milwaukee, USA) using a transducer frequency of 3.75 MHz. Renal morphology was studied in longitudinal and transverse planes. At least five Doppler spectra were obtained from more than three regions in each kidney in every study [15].

The data from dogs of the three groups were compared at different times of assessment, with statistical analyses by the

two-tailed Student's *t*-test, with  $P < 0.05$  considered to indicate significance.

## Results

All dogs survived the experiments without complications at sham surgery, after induction of UO or after vesico-ureteric re-implantation. An unobstructed pattern of the isotope renographic curve and a half-time drainage of  $< 10$  min showed relief of obstruction after vesico-ureteric re-implantation in all dogs with obstruction.

The mean values of CCr of the left kidney were comparable among dogs of the three groups at baseline; the sham-operated group showed stable CCr levels of the left kidney for the duration of the study (Fig. 1). By the end of the fourth week of obstruction, the mean (SD) values of CCr of both the enalapril and control groups were significantly lower than in the sham group. The value for the enalapril group, at 33.1 (2.5) mL/min, was significantly higher than that of 30.0 (1.4) mL/min in the control group at the end of the fourth week of obstruction ( $P < 0.01$ ; Fig. 1). The CCr in the enalapril group, at 37.9 (1.8) mL/min, was also significantly higher than that of the control group, at 33.8 (2.6) mL/min, by the end of the eighth week after relief of obstruction ( $P < 0.01$ ; Fig. 1).

At 4 weeks of obstruction the percentage decrease in the CCr was significantly lower in the enalapril group; compared to the control group, enalapril was associated with a lower reduction of CCr at 4 weeks of UO by 11% of the basal value. The ability of the kidney to regain its function at 8 weeks after relief of UO was significantly better in the enalapril than in the control group; enalapril enhanced the recovery of CCr at 8 weeks after relief of UO by an extra 10% of the baseline value compared with the control group.

The mean values of split renographic clearance (RCr) of the left kidney were comparable among dogs of the three groups at baseline. The sham group showed a stable split RCr level of the left kidney during the study (Fig. 2).

By the end of the fourth week of obstruction, the mean values of split RCr of both the enalapril and control groups were

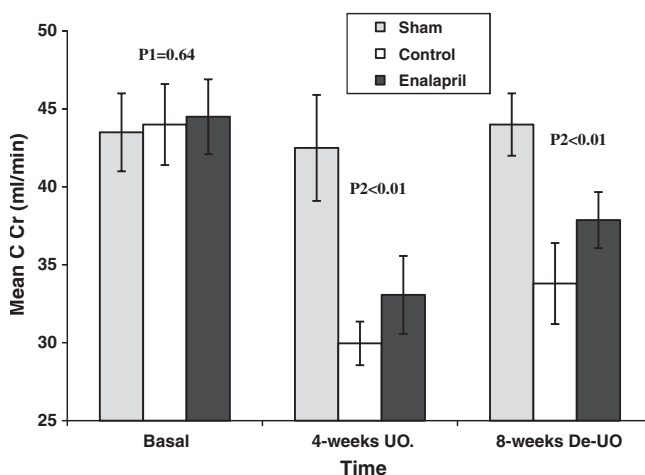
significantly lower than for the sham group. The mean value of split RCr of the enalapril group, at 26.5 (3.9)%, was significantly higher than that in the control group, at 20.8 (3.1)% at the end of the fourth week of UO ( $P < 0.01$ ; Fig. 2). The split RCr in enalapril group was significantly higher than in the control group at 4 and 8 weeks after relief of UO (Fig. 2). At 4 weeks of UO the percentage decrease in split function of the corresponding kidney was significantly lower in the enalapril group. Compared with the control group, enalapril offset the reduction of split RCr at 4 weeks of UO by 12% of the baseline value. The ability of the kidney to regain its function at 8 weeks after relief of UO was significantly better in the enalapril than in the control group. Enalapril enhanced the recovery of split RCr at 8 weeks after relief of UO by an extra 23% of the baseline compared with the control group.

All renal units in the three groups showed satisfactory DUS examinations. There was no significant difference in the mean (sd) RI of the left kidney of the sham, control and enalapril groups, at 0.42 (0.04), 0.47 (0.03) and 0.47 (0.04), respectively, at baseline. The mean RI of the sham-operated group remained stable during the study (Fig. 3).

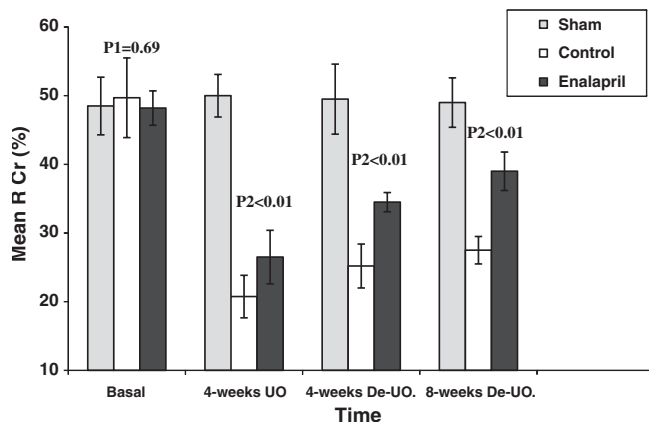
After 4 weeks of obstruction there was a significant increase in mean renal RI from 0.47 (0.03) to 0.71 (0.02) in the control group, and from 0.47 (0.04) to 0.61 (0.03) in the enalapril group ( $P < 0.001$  in both). By the end of the fourth week of obstruction, the mean RI of the enalapril group, at 0.61 (0.03), was significantly lower than that of the control group, at 0.71 (0.02) ( $P = 0.01$ ). There was a marked decrease in the RI to near baseline values at 4 weeks after relief of UO in both the control, at 0.48 (0.02), and the enalapril, at 0.50 (0.04), groups. The follow-up of RI at 8 weeks after relief of UO showed almost stable values similar to those at 4 weeks after relief of UO, in both the control and study groups (Fig. 3).

## Discussion

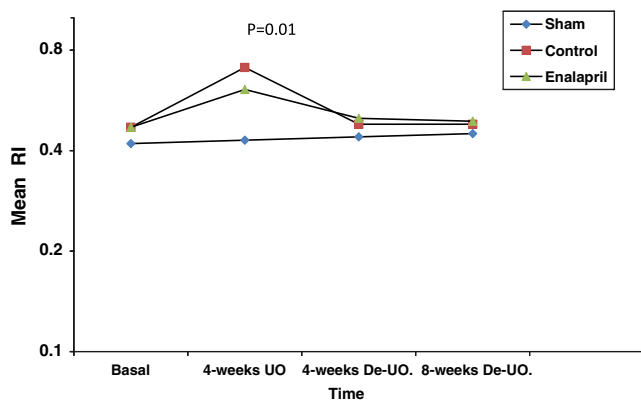
Partial UO is a frequent clinical finding in patients with ureteric stones under medical treatment, those passing stone fragments after ESWL, those awaiting treatment and in some



**Figure 1** Changes in the CCr of the left kidney after 4 weeks of UO and 8 weeks after relief of UO in the control and enalapril groups, and in the sham group at baseline, 4 and 8 weeks after sham surgery ( $P_1$  = enalapril vs control vs sham;  $P_2$  = enalapril vs control).



**Figure 2** Changes in the split RCr of the left kidney after 4 weeks of UO, and 4 and 8 weeks after relief of UO in the enalapril and control groups, and in the sham group at baseline, 4 and 8 weeks after sham surgery ( $P_1$  = enalapril vs control vs sham;  $P_2$  = enalapril vs control).



**Figure 3** Changes in the renal RI of the left kidney after 4 weeks of UO, and 4 and 8 weeks after relief of UO in the enalapril and control groups, and in the sham group at baseline, 4 and 8 weeks after sham surgery ( $P =$  enalapril vs control).

patients with an equivocal diagnosis of partial UO. In such situations, using medication which can protect the kidney against the harmful effects of UO is clinically very important. The obvious treatment for obstructive uropathy is the relief of UO, but some studies showed that the harmful effects of renal obstruction might continue even after relieving the UO [16]. Therefore, a search for drugs that can augment the recoverability of renal function after relieving UO would be invaluable.

The present study was a controlled experiment aiming to evaluate the role of an ACE inhibitor (enalapril) in protecting the kidney during the obstructive phase of chronic partial UUO, and to determine its role in the improvement of recoverability of renal function after relieving UO; as far as we are aware, these objectives have not been achieved in previous reports.

Previous studies reported the reno-protective effect of enalapril in complete UUO. It attenuates the progression of the fibrogenic process of UUO [5] and reduces the monocellular infiltration of the kidney by monocytes/macrophages [6]. In a recent study, enalapril decreased fibrosis, apoptosis and TGF- $\beta$  expression in the obstructed kidney [7]. Treatment with enalapril prevented angiotensin II-stimulated circulating lymphocyte apoptosis, resulting in an improvement in lymphocyte cell immunity and the host defense mechanism [8].

The present study showed, for the first time, that enalapril can also protect renal function during partial UUO. Enalapril significantly prevented the deterioration of both chemical and RCr of canine kidneys subjected to partial UUO for 4 weeks. Compared with the control, enalapril ameliorated the reduction of split renal function at 4 weeks of UO by 12% of the baseline value.

In a previous study, TNF- $\alpha$  and TGF- $\beta$  mRNA and their proteins were reduced to near normal levels, and  $\alpha$ -smooth muscle actin expression and myofibroblast proliferation were inhibited with enalapril treatment [9]. After release of UUO, enalapril accelerated remodeling of the renal interstitium in rats [10], and stimulated the production of nitric oxide through an increased expression of the endothelin receptor [11].

Treatment with the ACE inhibitor quinapril resulted in markedly diminished tubular lesions and inflammatory cell infiltration compared with untreated groups, implicating angiotensin II in renal damage progression after UUO. Behar-

rie et al. [17] examined weanling male rats that had been subjected to partial UUO; the partial UO led to proteinuria and hyperuricaemia, but a parallel group of rats treated with the ACE inhibitor enalapril was protected from these changes. This suggests that angiotensin is also involved with functional tubular changes [17]. In UUO, ACE inhibitor prevented the increase in renal vascular resistance in response to angiotensin-II in the rat kidney [18].

Several investigators reported various factors that might affect the recovery of renal function after relief of UO, including the duration of obstruction, function of the contralateral kidney, age, pyelo-lymphatic backflow, compliance of the ureter and renal pelvis, presence or absence of infection, concurrent nephrotoxic medications, contrast materials and dysplasia in the kidney [19–21]. In dogs with complete UUO for 7 days, the GFR at 1 h after the relief of UO was 25% of the basal GFR, and maximum recovery was 58% of the baseline, and this occurred within 57 days [22]. Similar studies were conducted by Vaughan and Gillenwater, who showed full functional renal recovery at 2 weeks after a 7-day period of complete UUO in dogs. This result declined to 70% recovery of GFR after 14 days of UUO, 30% after 4 weeks of UUO, and no recovery after 6 weeks of UUO [23].

Klahr and Morrissey [24] showed that bone morphogenic protein 7, a structural relative of TGF- $\beta$ , was effective in preventing the tubulointerstitial changes and accelerating the return of renal function in a rat model of UO. They showed that this agent inhibited apoptosis. This group also reported that the administration of hepatocyte growth factor has similar beneficial effects, and proposed that it works by suppressing expression of TGF- $\beta$  and platelet-derived growth factor. Pirfenidone is a drug that purportedly inhibits collagen synthesis, down-regulates the production of several cytokines, and blocks fibroblast proliferation. It might be another candidate to attenuate UO-induced renal injury and facilitate renal remodeling [25].

To the best of our knowledge, the effect of enalapril on the enhancement of recoverability of renal function after relief of UUO has not been studied previously. In the present study we showed that, compared with the control, enalapril can enhance the recovery of RCr at 8 weeks after relieving a 4-week UO by 23% of the basal value.

The induction of UUO is associated with an increase in the renal RI of the obstructed kidneys that is normalized after relief of UO, whatever its degree [21–26]. In our study the increase in RI was significantly less in the enalapril group. The significant decrease of renal RI in enalapril-treated dogs is a result of decreased vascular resistance due to its vasodilatory effect on the renal vasculature. This mechanism might explain the protective effect of enalapril against UUO.

In conclusion, enalapril decreases the deterioration of renal function in partial UUO and enhances the recoverability of renal function after relief of UO. Other studies should be conducted to consolidate our results before recommending the use of enalapril in clinical practice for managing patients with obstructive uropathy.

## References

- [1] Klahr S, Morrissey J. Comparative effects of ACE inhibition and angiotensin II receptor blockade in the prevention of renal damage. *Kidney Int Suppl* 2002;**82**:23–6.

- [2] Klahr S, Morrissey J. Comparative study of ACE inhibitors and angiotensin II receptor antagonists in interstitial scarring. *Kidney Int Suppl* 1997;**63**:S111-4.
- [3] Chevalier RL, Chung KH, Smith CD, Ficenc M, Gomez RA. Renal apoptosis and clusterin following ureteral obstruction. The role of maturation. *J Urol* 1996;**156**:1474-9.
- [4] Chevalier RL, Cachat F. Role of angiotensin II in chronic ureteral obstruction. *Contrib Nephrol* 2001;**135**:250-60.
- [5] Gonçalves RG, Biato MA, Colosimo RD, Martinusso CA, Pecly ID, et al. Effects of mycophenolate mofetil and lisinopril on collagen deposition in unilateral ureteral obstruction in rats. *Am J Nephrol* 2004;**24**:527-36.
- [6] Morrissey JJ, Klahr S. Differential effects of ACE and AT1 receptor inhibition on chemoattractant and adhesion molecule synthesis. *Am J Physiol* 1986;**274**:F580-6.
- [7] El Chaar M, Chen J, Seshan S, Jha S, Richardson I, Ledbetter SR, et al. The effect of combination therapy with enalapril and the TGF- $\alpha$  antagonist ID11 in unilateral ureteral obstruction. *Am J Physiol Renal Physiol* 2007;**292**:F1291-301.
- [8] Eiam-Ong S, Udom J, Sueblinvong T, Eiam-Ong S. Apoptosis of circulating lymphocyte in rats with unilateral ureteral obstruction: role of angiotensin II. *Nephrology (Carlton)* 2005;**10**:464-9.
- [9] Guo G, Morrissey J, McCracken R, Tolley T, Liapis H, Klahr S. Contributions of angiotensin II and tumor necrosis factor- $\alpha$  to the development of renal fibrosis. *Am J Physiol Renal Physiol* 2001;**280**:F777-85.
- [10] Koo JW, Kim Y, Rozen S, Mauer M. Enalapril accelerates remodeling of the renal interstitium after release of unilateral ureteral obstruction. *In Rats J Nephrol* 2003;**16**:203-9.
- [11] Moridaira K, Morrissey J, Fitzgerald M, Guo G, McCracken R, et al. ACE inhibition increases expression of the ETB receptor in kidneys of mice with unilateral obstruction. *Am J Physiol Renal Physiol* 2003;**284**:F209-17.
- [12] Shokeir AA. Partial ureteral obstruction. A new variable reversible canine experimental model. *Urology* 1995;**45**:953-7.
- [13] Paget GE, Barnes JM, Lawranle DR, Bacharch AL, editors. *Evaluation of drug activities, pharmacometrics*, Vol. 1. New York: Academic press; 1964.
- [14] Edelstein CL, Cronin RE. The patient with acute renal failure. In: Schrier RW, editor. *Manual of Nephrology*. London: Lippincott Williams & Wilkins; 2000. p. 132.
- [15] Shokeir AA, Nijman RJM, El-Azab M, Provoost AP. Partial ureteric obstruction: a study of Doppler ultrasonography and diuretic renography in different grades and duration of obstruction. *Br J Urol* 1996;**78**:829-35.
- [16] Ito K, Chen J, El Chaar M, Stern JM, Seshan SV, et al. Renal damage progresses despite improvement of renal function after relief of unilateral ureteral obstruction in adult rats. *Am J Physiol* 2004;**287**:F1283-93.
- [17] Beharrie A, Franc-Guimond J, Rodriguez MM, Au J, Zilleruelo CL, Abitbol CL. A functional immature model of chronic partial ureteral obstruction. *Kidney Int* 2004;**65**:1155-61.
- [18] Hilchey S, Quilley J, Bell-Quilley C. Vascular and excretory effects of angiotensin II in the rat isolated perfused kidney: influence of an AT1 and a nonselective AT receptor antagonist. *Pharmacology* 1998;**57**:196-205.
- [19] Chevalier RL, Thornhill BA, Wolstenholme JT. Renal cellular response to ureteral obstruction. Role of maturation and angiotensin II. *Am J Physiol* 1999;**277**:F41-7.
- [20] Shi Y, Pedersen M, Li C, Wen JG, Thomsen K, et al. Early release of neonatal ureteral obstruction preserves renal function. *Am J Physiol Renal Physiol* 2004;**286**:F1087-99.
- [21] Shokeir AA, Provoost AP, Nijman RJ. Resistive index in obstructive uropathy. *Br J Urol* 1997;**80**:195-200.
- [22] Kerr Jr WS. Effect of complete ureteral obstruction for one week on kidney function. *J Appl Physiol* 1954;**6**:762-72.
- [23] Vaughan Jr ED, Sorenson EJ, Gillenwater JY. The renal hemodynamic response to chronic unilateral complete ureteral occlusion. *J Urol* 1970;**8**:78-90.
- [24] Klahr S, Morrissey J. Obstructive nephropathy and renal fibrosis. The role of bone morphogenic protein-7 and hepatocyte growth factor. *Kidney Int Suppl* 2003;**87**:105-12.
- [25] Lasky J. Pirfenidone I. *Drugs* 2004;**7**:166-72.
- [26] Platt JF, Rubin JM, Ellis HM, Di Pietro MA. Duplex Doppler US of the kidney. Differentiation of obstructive from non-obstructive dilatation. *Radiology* 1989;**17**:515-7.