



Immature Teratoma of the Ovary: A Case Report and Literature Review

Taha Kabbaj ^{a*}, Kaid Mohamed ^a, Othman Alaoui ^a,
Moustapha Elwaled ^a, Imad Laamri ^a, El Bahaoui Nezha ^a
and Hachi Hafid ^a

^a Breast Gynecology Department, National Institute of Oncology, University Mohammed V in Rabat, Rabat, Morocco.

Authors' contributions

This work was carried out in collaboration among all authors. All authors read and approved the final manuscript.

Article Information

Open Peer Review History:

This journal follows the Advanced Open Peer Review policy. Identity of the Reviewers, Editor(s) and additional Reviewers, peer review comments, different versions of the manuscript, comments of the editors, etc are available here: <https://www.sdiarticle5.com/review-history/125338>

Case Report

Received: 27/08/2024

Accepted: 29/10/2024

Published: 15/11/2024

ABSTRACT

Immature teratomas are rare malignant tumors representing less than one percent of ovarian teratomas, occurring in young women and adolescents. Their development arises from cells derived from the three embryonic germ layers (endoderm, mesoderm, and ectoderm). They are classified into three grades of increasing severity based on the proportion of immature neural cells. The prognosis is directly correlated with the histological grade. The therapeutic management is primarily surgical, possibly combined with adjuvant chemotherapy, while maximizing the preservation of fertility potential.

Keywords: *Immature teratoma; ovary; tumor; chemotherapy; surgery.*

*Corresponding author: E-mail: taha.kabbaj.chuis@gmail.com;

Cite as: Kabbaj, Taha, Kaid Mohamed, Othman Alaoui, Moustapha Elwaled, Imad Laamri, El Bahaoui Nezha, and Hachi Hafid. 2024. "Immature Teratoma of the Ovary: A Case Report and Literature Review". *Asian Journal of Research in Surgery* 7 (2):457-63. <https://journalajrs.com/index.php/AJRS/article/view/244>.

1. INTRODUCTION

Immature teratoma is a non-seminomatous germ cell tumor first described in 1960 by Thürlbeck and Scully [1]. Immature teratomas are very rare, accounting for less than one percent of malignant ovarian tumors. Their classification into three grades of malignancy was initially proposed by Thurlbeck and Scully [1] and modified in 1976 by Norris and O'Connor to better define therapeutic indications [2]. However, the management of immature teratoma remains controversial due to the rarity of these tumors, which limits sufficient studies comparing different therapies. We report the case of a 17-year-old patient admitted to the gynecological and breast unit of the National Institute of Oncology CHU-Ibn Sina for the management of an abdominopelvic mass. She underwent an abdominopelvic CT scan and pelvic MRI, followed by surgical treatment involving a right adnexectomy and several biopsies. The histological examination confirmed an immature ovarian teratoma. The aim of this study is to highlight the diagnostic challenges, the evolution of this type of ovarian tumor, and to discuss management modalities.

2. CASE REPORT

A 17-year-old patient with no medical or surgical history, unmarried, was admitted to our hospital for the management of pelvic pain in the context of a general state alteration. Examination revealed a round, non-tender abdominopelvic mass reaching the umbilicus. The pelvic CT scan showed a complex cystic abdominopelvic mass containing a non-enhancing tissue component after contrast injection, calcification, and a fatty compartment, measuring 109 x 104 x 143 mm in its largest dimensions (Fig. 1). MRI revealed a large mixed abdominopelvic mass containing a fleshy portion, roughly oval in shape, with lobulated contours, surrounded by a capsule with septations, measuring approximately 144 x 117 x 190 mm (Fig. 2). The CA 125 level was elevated at 78.9 U/ml (0–35 U/ml); B HCG was negative; LDH was 162 U/L (125–220 U/L); and AFP was 5.29 ng/ml (0.89–8.78 ng/ml). The patient underwent laparotomy, which revealed a large ovarian mass on the right ovary, leading to right adnexectomy, peritoneal cytology, peritonectomy, omentectomy, and removal of a polyp from the Douglas pouch

(Fig. 3). The pathological results confirmed a grade 2 immature teratoma of the ovary and a secondary localization in the Douglas pouch. The omentectomy and peritonectomy did not contain any cancer cells. Peritoneal fluid cytology was negative. The case was presented to the multidisciplinary oncology team, and the decision for adjuvant chemotherapy and oocyte cryopreservation was made.

3. DISCUSSION

Immature teratoma of the ovary is a malignant tumor composed of tissues derived from the three embryonic cell lineages (mesoderm, endoderm, and ectoderm) present at various stages of maturation within the tumor [3].

Immature teratomas preferentially affect young women in their second decade of life; however, cases have been described in the literature across all ages, including postmenopausal women [4,5]. In our observation, the patient was 17 years old. Immature teratoma represents 3% of teratomas, 1% of all ovarian cancers, and 20% of malignant germ cell tumors of the ovary [3]. Typically, immature teratomas present as a rapidly enlarging abdominopelvic mass associated with increased abdominal volume and a sensation of pelvic heaviness, as seen in our case. There is usually no alteration in general health or menstrual cycle disturbances. In our observation, however, there was a general health alteration with significant weight loss. A retrospective analysis of 24 women who presented to a gynecologic oncology unit from 1999 to 2011 with ovarian immature teratoma showed that over 24 patients had pain as the predominant symptom and abdominal mass was the commonest clinical presentation [6]. However, in our case, the patient didn't complain from any pain and the main symptom that urged her medical consultation was the abdominal pelvic mass.

It can also be discovered as a complication related to tumor volume: torsion or compression of neighboring organs [7]. This tumor is generally unilateral, large, rounded, unilobulated or multilobulated, and has a mixed liquid and solid component [8]. The contralateral ovary presents a mature teratoma in 26% of cases and another immature teratoma in 10% of cases [9].

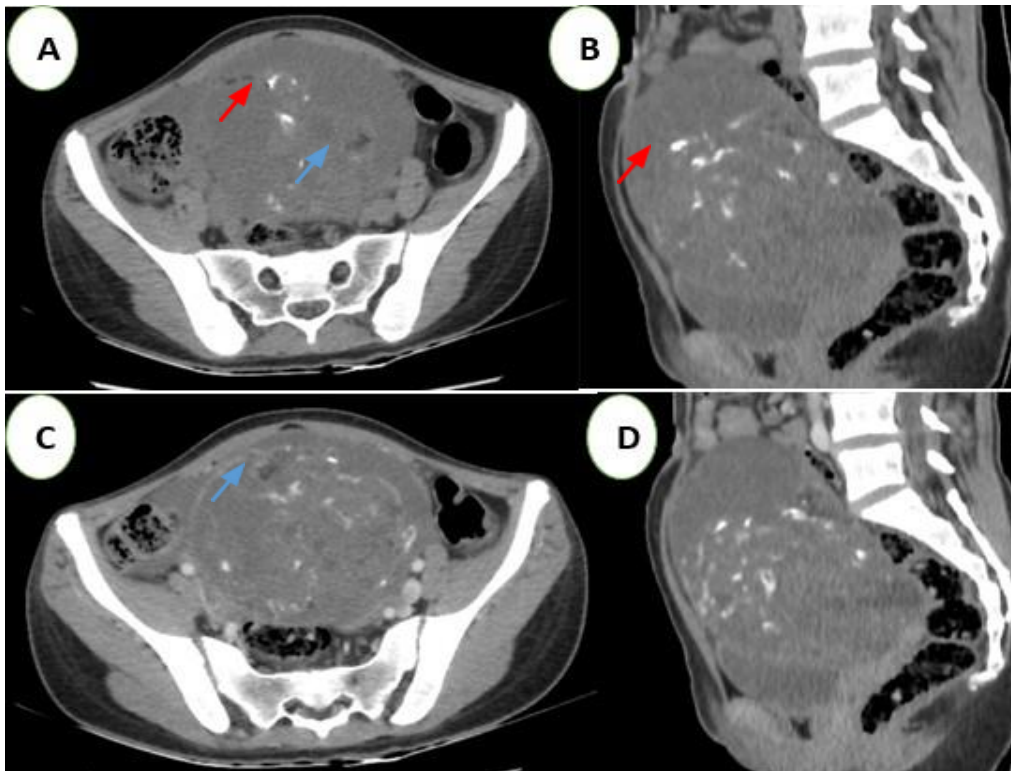


Fig. 1. Abdominopelvic CT Scan without (A and B) and with contrast injection (C and D), in axial (A and C) and sagittal (B and D) slices

A large heterogeneous abdominopelvic mass, predominantly fluid-filled and non-enhancing after contrast injection, containing fatty areas (blue arrow) and calcifications (red arrow) consistent with a teratoma

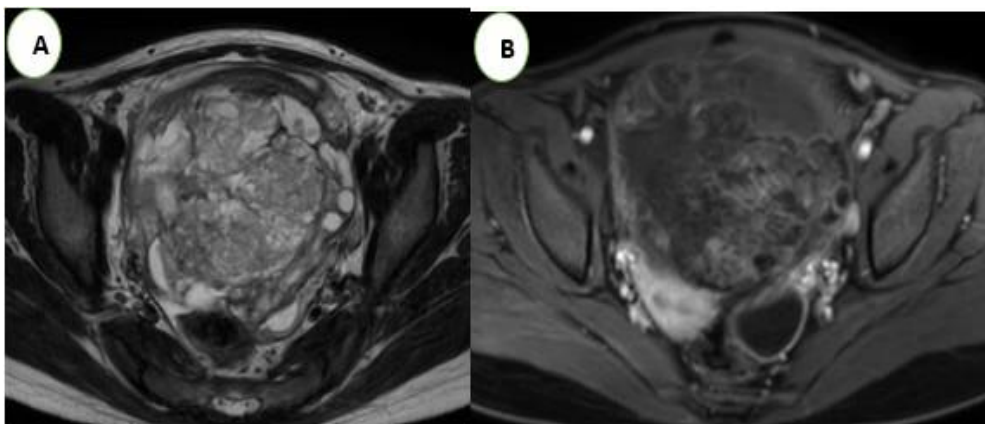


Fig. 2. Pelvic MRI T2 axial sequences (A) and T1 FATSAT with gadolinium injection (B) of the same patient confirming the ovarian origin of the teratoma

In imaging, immature teratoma is a large tumor (12—25 cm) [10]. The ultrasound appearance of immature teratomas is nonspecific [11]. CT and MRI images are more characteristic. Generally, on the scan, immature teratomas are rarely cystic and present as a large, irregular tumor of mixed tissue and fatty appearance, with the solid

part consisting of numerous coarse and amorphous calcifications associated with scattered fatty islands and some rare microcysts [12,13]. In our case, the CT showed a complex cystic abdominopelvic mass containing a non-enhancing tissue component, calcifications, and a fatty compartment, while MRI highlighted the

presence of a large mixed abdominopelvic mass containing a fleshy portion with lobulated contours and a capsule emitting septations. Imaging plays an important role in orienting the diagnosis, but the anatomical-pathological study confirms the diagnosis.

The immature teratoma of the ovary consists of a mixture of mature and immature tissue in varying proportions, and the amount of immature neural tissue allows for classification into three grades of increasing malignancy. This

classification was initially proposed by Thurlbeck and Scully and modified in 1976 by Norris and O'Connor to better define therapeutic indications [1,2] (Table 1). Currently, this classification tends to be simplified into low and high grades [13]. Tumors with a better prognosis are grade 1 tumors, for which the five-year survival rate is estimated between 81 and 94% [7,14,15]. Grade 3 immature teratomas have a highly malignant potential and their rapid evolution, both locally and distally, results in higher rates of recurrence and mortality [7,14,15].

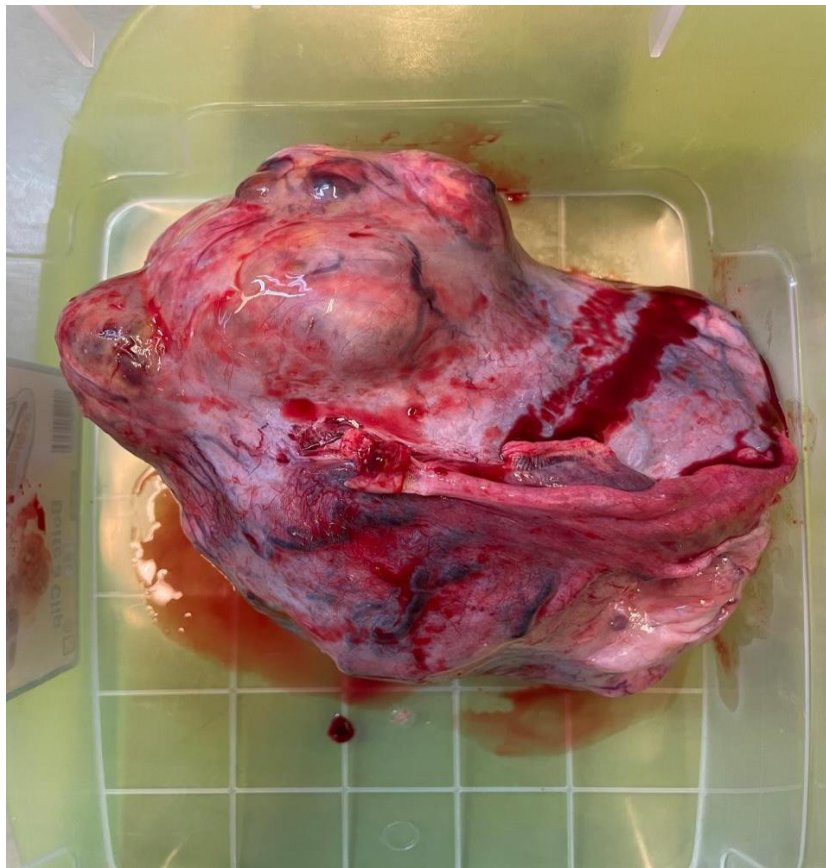

Fig. 3. Operative specimen of an immature teratoma from our patient

Table 1. Grading of immature ovarian teratomas by Norris and O'Connor (in 3 grades)

Grade0	Fully mature tissue with rare mitotic activity.
Grade1	Tumor containing rare areas of immature neuroepithelial tissue occupying less than one field per slide at 40x magnification.
Grade2	Tumor containing rare areas of immature neuroepithelial tissue occupying 1 to 3 fields per slide at 40x magnification.
Grade3	Tumor containing large areas of immature neuroepithelial tissue occupying more than 3 fields per slide at 40x magnification.

The measurement of serum tumor markers is common in the discovery of an ovarian tumor. Tumor markers can assist in diagnosis, prognosis evaluation, and post-therapeutic follow-up. A nonspecific elevation of CA 125 can be found in cases of immature teratoma, as in many pelvic pathologies [16].

Alpha-fetoprotein may be elevated in 18 to 45% of cases [16,17]. A serum level above 400 ng is considered a risk factor for poor progression. Lactate dehydrogenase (LDH), often used as a tumor marker to evaluate tumor burden in malignant germ cell tumors, can reflect rapid cell proliferation and high metabolism within the tumor. This may be observed in immature teratomas, although LDH is less specific than AFP. CA 19.9 is also being evaluated, and very high levels have been found in some cases of immature teratomas, but the role of this marker is still to be determined [7]. Human chorionic gonadotropin (β -hCG) can also be slightly elevated in some immature teratomas that contain trophoblastic elements [16,17]. In our patient, CA 125 was elevated at 78.9 U/ml, and the other tumor markers were negative.

In terms of treatment, according to the French Society of Oncology in 2013, the management of immature teratomas is divided into two parts: surgical treatment followed by chemotherapy depending on the histological grade.

Surgical treatment generally constitutes the first therapeutic step, involving unilateral ovariectomy or initial adnexectomy through a midline laparotomy, allowing for simultaneous exploration of the abdominal cavity with peritoneal fluid collection for cytological study and systematic multiple peritoneal biopsies, including at the epiploon and collection of any suspicious element. Systematic pelvic and lumbar-aortic lymphadenectomy is not recommended in the absence of lymph node abnormalities. A sample will be taken if an anomaly is detected by CT or during surgical exploration [18,19]. A meticulous inspection of the contralateral ovary is necessary since the contralateral ovary presents a mature teratoma in 26% of cases and another immature teratoma in 10% of cases [9], although systematic bilateral adnexectomy is not indicated. However, it is certain that more aggressive treatment such as hysterectomy and contralateral adnexectomy, which would definitively eliminate any possibility of future

pregnancy, is unnecessary [20]. The coloscopic approach is rarely used due to the size of the tumor; treatment must take into account the preservation of fertility, as immature teratoma of the ovary is generally a tumor of young women.

In our observation, we opted for conservative treatment to preserve fertility in our 17-year-old patient, with peritoneal biopsies. We performed laparotomy, which revealed a large ovarian mass on the right ovary, leading to right adnexectomy, peritoneal cytology, peritonectomy, omentectomy, and removal of a polyp from the Douglas pouch. The pathological study confirmed a grade 2 immature teratoma of the ovary and a secondary localization in the Douglas pouch.

Adjuvant chemotherapy is determined by the histological grade. For grade 1 tumors, clinical follow-up after conservative surgery suffices, with no long-term recurrence observed according to a study by Carinelli on 245 cases of immature ovarian teratomas after unilateral adnexectomy [21]. Adjuvant chemotherapy is usually reserved for grade 3 tumors or even grade 2 tumors. Reports revealed that VAC (vincristine, dactinomycin, and cyclophosphamide) was very active for patients with stage I disease, but rather ineffective for those with advanced-stage tumors [22]. Because equal efficacy and less toxicity favored the combination of bleomycin, etoposide and a platinum salt cisplatin (BEP) as standard treatment for malignant OGCT in the 1990s, subsequent reports further confirmed the BEP regimen as first-line therapy for OGCT [23,24].

Therefore, the most commonly used protocol includes three agents borrowed from testicular cancer chemotherapy: BEP [19,21,25]. For our patient, during the multidisciplinary meeting and considering the histological grade and the location on the polyp removed from the Douglas pouch, adjuvant chemotherapy was indicated according to the BEP protocol with oocyte cryopreservation. The cryopreservation was not performed due to the patient's lack of means.

A recent study by Cushing et al. contradicts the necessity of chemotherapy, showing that surgery alone provides a curative treatment in the majority of cases, regardless of the initial tumor grade, with a four-year survival rate of 100% and 97.7% of patients without recurrence. The authors conclude that chemotherapy should be reserved for post-surgical recurrences to avoid

the adverse effects of chemotherapy in patients who are often very young [18,19].

4. CONCLUSION

Immature teratoma of the ovary is a malignant tumor whose severity and prognosis depend directly on the histological grade, indicating the tumor's aggressiveness. It primarily affects young women, and diagnosis is usually suspected through radiological examinations before being confirmed by pathological examination. The recommended treatment favors a conservative surgical approach to preserve fertility as much as possible. Depending on the tumor grade, chemotherapy may be necessary to complete treatment.

DISCLAIMER (ARTIFICIAL INTELLIGENCE)

Author(s) hereby declare that NO generative AI technologies such as Large Language Models (ChatGPT, COPILOT, etc) and text-to-image generators have been used during writing or editing of this manuscript.

CONSENT

As per international standards or university standards, patient(s) written consent has been collected and preserved by the author(s).

ETHICAL APPROVAL

As per international standards or university standards written ethical approval has been collected and preserved by the author(s).

COMPETING INTERESTS

Authors have declared that no competing interests exist.

REFERENCES

1. Thurlbeck WM, Scully RE. Solid teratoma of the ovary. A clinicopathological analysis of 9 cases. *Cancer*. 1960;13:804–11.
2. Norris HJ, Zirkin HJ, Benson WL. Immature (malignant) teratoma of the ovary: a clinical and pathologic study of 58 cases. *Cancer*. 1976;37(5):2359–72.
3. Norris JH, O'Connor MD. Pathology of malignant germ cell tumors of the ovary. In: Coppleson M, editor. *Gynaecologic*

- Oncology. Second edition. Hong Kong: Longman Group (FE) Ltd; 1992.
4. Doss BJ, Jacques SM, Qureshi F, Chang CH, Christensen CW, Morris RT, et al. Immature teratomas of the genital tract in older women. *Gynecol Oncol*. 1999;73(3): 433–8.
5. Sutton CL, McKinney CD, Jones JE, Gay SB. Ovarian masses revisited: Radiologic and pathologic correlation. *Radiographics*. 1992;12(5):853–77.
6. Immature teratoma of ovary – outcome following primary and secondary surgery: Study of a single institution cohort. Reddihalli, Pallavi V. et al. *European Journal of Obstetrics and Gynecology and Reproductive Biology*. 192:17-21
7. Noun M, Ennachit M, Boufettal H, Elmouatacim K, Samouh N. Immature teratoma of the ovary with peritoneal gliomatosis. About a case and review of the literature Published by Elsevier Masson SAS. 2007.04.005; 2007.
8. Outwater EK, Siegelman ES, Hunt JL. Ovarian teratomas: Tumor types and imaging characteristics. *Radiographics*. 2001;21(2):475–90.
9. Yamaoka T, Togashi K, Koyama T, Fujiwara T, Higuchi T, Iwasa Y, et al. Immature teratoma of the ovary: Correlation of MR imaging and pathologic findings. *Eur Radiol*. 2003;13(2):313–9.
10. Laura Elkinda, Aurélie Jalaguier-Coudraya, Eric Lambaudieb, Rim Villard-Mahjoubaa, Béatrice Delarbrea, Valérie Juhand, Jeanne Thomassin-Pianaee, Gilles Houvenaeghelb, Immature ovarian teratoma in a 38-year-old patient: Value of preoperative pelvic MRI Elsevier Masson SAS. 2014.11.002; 2014.
11. Sutton CL, McKinney CD, Jones JE, Gay SB. Ovarian masses revisited: radiologic and pathologic correlation. *Radiographics*. 1992;12(5): 853-77.
12. Bazot M, Cortez A, Sananes S, Boudghene F, Uzan S, Bigot JM. Imaging of dermoid cysts with foci of immature tissue. *J Comput Assist Tomogr*. 1999;23(5):703–6.
13. Rezk Y, Sheinfeld J, Chi DS. Prolonged survival following sal vage surgery for chemorefractory ovarian immature teratoma: A case report and review of the literature. *Gynecol Oncol*. 2005;96(Issue 3):883–7 13.

14. Kawata M, Sekiya S, Hatakeyama R, Takamizawa H. Neuron specific enolase as a serum marker for immature teratoma and dysgerminoma. *Gynecol Oncol.* 1989;32(2): 191–7.
15. Kawai M, Kano T, Kikkawa F, Morikawa Y, Oguchi H, Nakashima N, et al. Seven tumor markers in benign and malignant germ cell tumors of the ovary. *Gynecol Oncol.* 1992; 45(3):248–53
16. Kawata M, Sekiya S, Hatakeyama R, Takamizawa H. Neuron specific enolase as a serum marker for immature teratoma and dysgerminoma. *Gynecol Oncol.* 1989;32(2): 191–7.
17. Trabelsi A, Conan-Charlet V, Lhomme C, Morice P, Duvillard P, Sabourin JC. Peritoneal glioblastoma: Recurrence of an immature ovarian teratoma (case report). *Ann Pathol.* 2002; 22:130-133.
18. Cushing B, Giller R, Ablin A, Cohen L, Cullen J, Hawkins E et al. Surgical resection alone is effective treatment for ovarian immature teratoma in children and adolescents. *Am J Obstet Gynecol.* 1999; 181(2):353-8
19. Frédéric Selle. Germ cell tumors and malignant ovarian teratomas: Therapeutic management, HUEP (University Hospitals of Eastern Paris) Tenon Hospital. APHP, Paris; 2013.
20. Müller AM, Söndgen D, Stunz R, Müller KM. Gliomatosis perito nei: A report of two cases and review of the literature. *Eur J Obstet Gynecol Reprod Biol.* 2002;100: 213–22.
21. Kollmannsberger C, Oechesle K, Dohmen BM, Pfannenberger A, Bares R, Claussen CD, et al. Prospective comparison of [18F] fluorodeoxyglucose positron emission tomography with conventional assessment by computed tomography scans and serum tumor markers for the evaluation of residual masses in patients with non-seminomatous germ cell carcinoma. *Cancer.* 2002;94: 2353–62.
22. Slayton RE, Park RC, Silverberg SG, Shingleton H, Creasman WT, Blessing JA. Vincristine, dactinomycin, and cyclophosphamide in the treatment of malignant germ cell tumors of the ovary: A Gynecologic Oncology Group study (a final report). *Cancer.* 1985;56:243–8.
23. Segelov E, Campbell J, Ng M, Tattersall M, Rome R, Free K, Hacker N, et al. Cisplatin-based chemotherapy for ovarian germ cell malignancies: the Australian experience. *J Clin Oncol.* 1994;12:378–84
24. Homesley HD, Bundy BN, Hurteau JA, Roth LM. Bleomycin, etoposide, and cisplatin combination therapy of ovarian granulosa cell tumors and other stromal malignancies: A Gynecologic Oncology Group study. *Gynecol Oncol.* 1999;72:131–7
25. Le Goarant de Tromelin J, Deruelle P, Lucot JP, Collinet P. Evaluation of the management of immature ovarian teratomas: About three cases and review of the literature. *Obstetrics, Gynecology & Fertility.* 2005;33:594-9.

Disclaimer/Publisher's Note: The statements, opinions and data contained in all publications are solely those of the individual author(s) and contributor(s) and not of the publisher and/or the editor(s). This publisher and/or the editor(s) disclaim responsibility for any injury to people or property resulting from any ideas, methods, instructions or products referred to in the content.

© Copyright (2024): Author(s). The licensee is the journal publisher. This is an Open Access article distributed under the terms of the Creative Commons Attribution License (<http://creativecommons.org/licenses/by/4.0>), which permits unrestricted use, distribution, and reproduction in any medium, provided the original work is properly cited.

Peer-review history:

The peer review history for this paper can be accessed here:

<https://www.sdiarticle5.com/review-history/125338>