



## Pararectal Abscess Masquerading as an Ovarian Cyst: A Case Report

Kavita Khoiwal<sup>1\*</sup>, Reena Kumari<sup>1</sup>, Anshu Gupta<sup>1</sup>, Debasish Das<sup>1</sup>,  
Amrita Gaurav<sup>1</sup> and Jaya Chaturvedi<sup>1</sup>

<sup>1</sup>All India Institute of Medical Sciences, Rishikesh, India.

### **Authors' contributions**

*This work was carried out in collaboration among all authors. Author KK designed and produced majority of the manuscript. Authors KK, RK, AG, DD and AG were involved in the case management. Author JC critically analyzed the manuscript. Authors RK and AG obtained the clinical images. All authors read and approved the final manuscript.*

### **Article Information**

#### Editor(s):

(1) Dr. José Francisco de Sales Chagas, Sao Leopoldo Mandic Medical School, Brasil.

#### Reviewers:

(1) Atef Darwish, Assiut University, Egypt.

(2) Ahmed Muhammed Rabi Human, Federal University of Lafia, Nigeria.

Complete Peer review History: <http://www.sdiarticle4.com/review-history/64661>

Case Study

**Received 05 November 2020**

**Accepted 11 January 2021**

**Published 27 January 2021**

### **ABSTRACT**

Pararectal abscess usually present with severe perianal and/or perirectal pain with or without fever, and features of sepsis. Here, we report a case where pararectal abscess was diagnosed during laparoscopic surgery and initially misdiagnosed as ovarian cyst.

*Keywords: Pararectal abscess; masquerading; ovarian cyst.*

### **1. CASE DESCRIPTION**

A 42-year-old female P2L2A1 presented to the outpatient department with occasional episodes of bleeding per vaginum for 10 days. She had a history of medical termination of pregnancy (MTP) 3 weeks back. Her general physical examination was unremarkable. On speculum

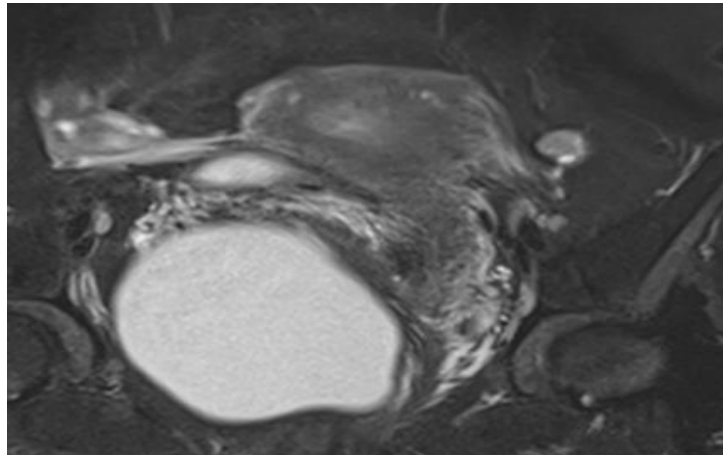
examination, a right posterolateral vaginal bulge was noted. Vaginal examination revealed the same bulge, pushed up cervix, and normal-sized uterus with fullness in right fornix. Rectal mucosa was free and well-defined, non-tender, cystic mass (12x10 cm) was felt in rectovaginal space on rectal examination. Ultrasound was suggestive of a 12x10 cm right adnexal cyst

\*Corresponding author: E-mail: kavita.kh27@gmail.com;

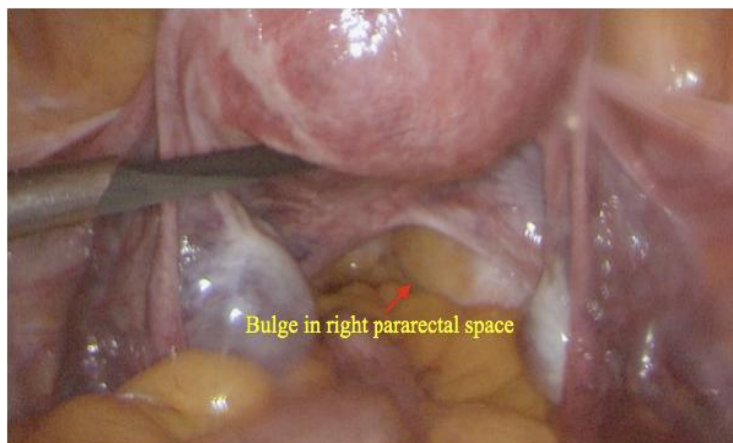
deep in the pelvis. To delineate the nature and origin of mass a contrast-enhanced magnetic resonance imaging (CEMRI) was ordered. CEMRI pelvis revealed a well-defined unilocular cystic lesion measuring 9.6x9.4x11.4 cm in pouch of Douglas with no septations and solid component suggestive of benign right ovarian cyst (Fig. 1). Uterus and left ovary were normal. Tumor markers were ordered to rule out ovarian malignancy; CA-125, CEA, AFP, and LDH were within normal limits whereas beta-hCG (137 IU/L) and CEA (167 U/L) were raised.

With the probable diagnosis of ovarian cyst, laparoscopic ovarian cystectomy +ovariotomy was planned. On diagnostic laparoscopy, bilateral ovaries were normal except a small follicular (3x2 cm) left ovarian cyst. Uterus and both fallopian tubes were normal. No obvious

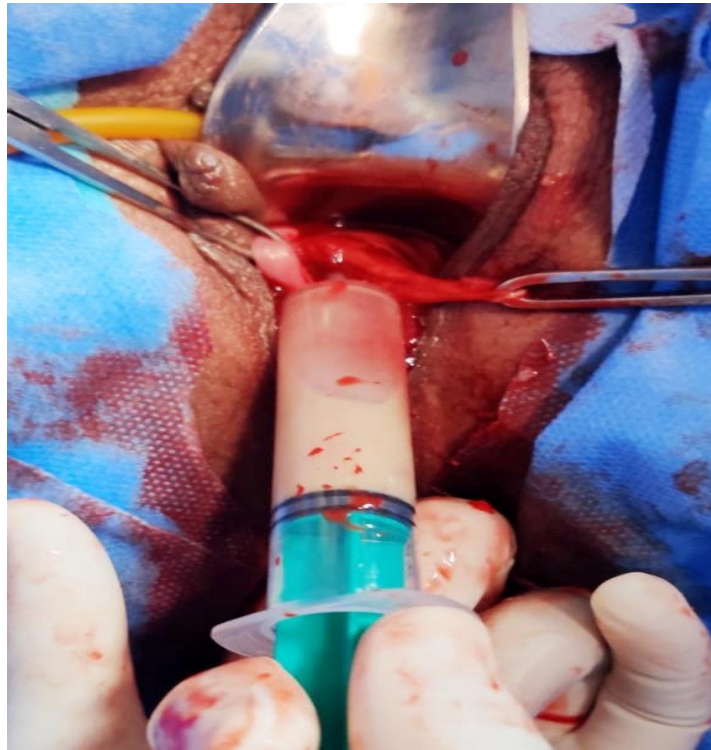cyst or cystic collection was noted in pelvis, yet a bulge was noted in the right pararectal space (Fig. 2). Vaginally, the bulge was quite high up and felt in right posterolateral vaginal wall. To confirm the nature of the cyst, its contents were aspirated with a syringe which turned out to be pus. A nick was made over the most prominent part of bulge and approximately 600ml of thick pus was drained (Fig. 3). The cyst wall was dissected off and an indwelling catheter was placed in the cavity for continuous drainage. Pus culture was suggestive of Escherichia coli growth and antibiotic was advised on basis of sensitivity. Final histopathology was suggestive of chronic inflammation and negative for granuloma or malignancy. The patient was discharged on 2nd postoperative day in stable condition. The consent for publication has been taken from the patient.



**Fig. 1. Contrast enhanced MRI showing right ovarian cyst**



**Fig. 2. Laparoscopic image showing normal findings except bulge in right pararectal space**



**Fig. 3. Vaginal drainage of pus from right pararectal abscess**

## **2. DISCUSSION**

Pararectal abscess accounts for 1 in 10,000 anorectal abscesses and comparatively less common than perianal abscesses [1,2]. It is three times less prevalent in women than men and mostly occurs from 30 to 40 years of age [3]. Predisposing factors include a history of trauma, Crohn's disease, tobacco abuse, immunosuppression, sexually transmitted disease, tuberculosis, carcinoma, radiation, or any foreign body [4,5]. The main causative organism is usually an aerobic or anaerobic bacteria from the skin, bowel, and, rarely, vagina. *Escherichia Coli* is one of the common organisms identified in such cases. These patients usually present with severe perianal and/or perirectal pain with or without fever, and features of sepsis. MRI is considered to be useful in diagnosis [6] and management includes prompt incision and drainage followed by appropriate antibiotics [7]. The diagnosis is usually easy, mostly clinical and confirmative on imaging.

But in our case, it was diagnosed incidentally during follow up of MTP. We could not think of pararectal abscess as a probable diagnosis

since there were no suggestive symptoms (i.e. pain, fever) and signs i.e. erythema, inflammation, induration, tenderness, and perineal discharge. Furthermore, radiology favors a different diagnosis. Our patient had no predisposing factors of pararectal abscess. Fortunately, got treated effectively by incision and drainage, placement of a drain, and injectable antibiotics. We could not find any similar cases reported in the literature.

## **3. CONCLUSION**

Pararectal abscess should be kept in mind as one of the diagnoses in cases of vaginal swelling even in absence of signs and symptoms. It can be proved fatal if not timely diagnosed and appropriately managed.

## **CONSENT AND ETHICAL APPROVAL**

As per university standard guideline patient consent and ethical approval has been collected and preserved by the authors.

## **COMPETING INTERESTS**

Authors have declared that no competing interests exist.

## REFERENCES

1. Turner SV, Singh J. Perirectal Abscess. Stat Pearls [Internet]. Treasure Island (FL): Stat Pearls Publishing; 2020. PMID: 29939672.
2. Whiteford MH. Perianal abscess/fistula disease. Clin Colon Rectal Surg. 2007; 20(2):102-9.
3. Sandhu G, Georgescu A, Korniyenko A, Florita C, Iuga A. Recurrent perirectal abscess. Am J Med. 2010;123(9):e13-4.
4. Marzo M, Felice C, Pugliese D et al. Management of perianal fistulas in Crohn's disease: An up-to-date review. World J Gastroenterol. 2015;356:1394-403.
5. Sahnun K, Adegbola SO, Tozer PJ, Wafah J, Phillips R. Perianal abscess. BMJ. 2017;356:j475.
6. Zbar AP, Armitage NC. Complex perirectal sepsis: Clinical classification and imaging. Tech Coloproctol. 2006;10:83-3.
7. Sözüner U, Gedik E, Kessaf Aslar A et al. Does adjuvant antibiotic treatment after drainage of anorectal abscess prevent development of anal fistulas? A randomized, placebo-controlled, double-blind, multicenter study. Dis Colon Rectum. 2011;356:923-9.

© 2021 Khoiwal et al.; This is an Open Access article distributed under the terms of the Creative Commons Attribution License (<http://creativecommons.org/licenses/by/4.0>), which permits unrestricted use, distribution, and reproduction in any medium, provided the original work is properly cited.

*Peer-review history:*  
*The peer review history for this paper can be accessed here:*  
<http://www.sdiarticle4.com/review-history/64661>