

Penetrating Ocular Trauma in a Goldfish Model after Chloramphenicol or Traditional Medicine Angong Niu Huang Pill Treatment: An Analysis of Retinal Responses after 7 Days

Rufina S. Y. Cheng¹, Gigi C. T. Leung², Tony C. H. Chow², Jocy T. C. Lee², Sharon L. Y. Wu^{1,2}, Linda S. L. Wu¹, David T. Yew^{1,2,3*}

¹School of Chinese Medicine, Faculty of Medicine, The Chinese University of Hong Kong, Shatin, China

²Hong Kong College of Technology, Shatin, China

³School of Biomedical Sciences, Faculty of Medicine, The Chinese University of Hong Kong, Shatin, China

Email: *david-yew@cuhk.edu.hk

How to cite this paper: Cheng, R.S.Y., Leung, G.C.T., Chow, T.C.H., Lee, J.T.C., Wu, S.L.Y., Wu, L.S.L. and Yew, D.T. (2022) Penetrating Ocular Trauma in a Goldfish Model after Chloramphenicol or Traditional Medicine Angong Niu Huang Pill Treatment: An Analysis of Retinal Responses after 7 Days. *Open Journal of Ophthalmology*, 12, 294-306. <https://doi.org/10.4236/ojoph.2022.123027>

Received: February 27, 2022

Accepted: August 27, 2022

Published: August 30, 2022

Copyright © 2022 by author(s) and Scientific Research Publishing Inc. This work is licensed under the Creative Commons Attribution International License (CC BY 4.0).

<http://creativecommons.org/licenses/by/4.0/>



Open Access

Abstract

Purpose: While there were numerous clinical examples of ocular damage, the histopathology of retinal responses was poorly characterized, and animal model research was limited. The consequences of retinal lesions with traditional medicine treatment were mostly unknown. In this work, goldfish was employed as a model for penetrating injury of the eyes to study the ocular trauma with antibiotic and traditional medicine treatments. **Materials and Methods:** The penetration of the eyes was performed at 2mm above the mid-line of the limbus in the superior quadrant with an 18-gauge sterile needle, all the way to the retina but avoiding the lens while the animals were anaesthetized in water containing 100 mg/L ethyl 3-aminobenzoate methanesulfonate (MS-222). The animals were divided into three groups and received treatments of saline, chloramphenicol, and Angong Niu Huang pill (Angong) eye-drops twice a day respectively. Angong after seven days, the animals were sacrificed. Immunohistochemical evaluation of proliferative cell nuclear antigen (PCNA), brain-derived neurotrophic factor (BDNF), catalase, and cleaved caspase-3, and terminal deoxynucleotidyl transferase dUTP nick end labeling (TUNEL) for apoptotic cells were performed on the fish's superior quadrants of the retinae. The whole experiment was repeated two times. **Result:** It was evident that both the retinae treated with chloramphenicol and Angong had fewer apoptotic cells and more proliferative cells, particularly in the cases of the Angong treatment. BDNF was in the inner nuclear layer and ganglion cell layer of all groups. In the chloramphenicol and Angong groups, some cells in

the outer nuclear layer displayed BDNF. Catalase reactions confirmed equivalent findings that the treated retinae with chloramphenicol or Angong treatment had less catalase. **Conclusion:** Angong Niuhuang pill is a traditional medicine composite formula with antibiotic and neuroprotective effects on the brain and the eyes, and this work also pointed out its possible pharmaceutical potential.

Keywords

Ocular Trauma, Goldfish, Chloramphenicol, Traditional Medicine, Angong Niuhuang Pill

1. Introduction

Ocular trauma is an eye problem resulting from injury, and 40% of monocular traumas usually come from children at school or at home. Adults might also be affected, especially young males of 18 - 24 years old, usually as a result of injury from sport, assault or accidents [1]. Apart from designating the injury as close or open, the classification of global, adnexal, or mechanical injury could also be used [2]. Penetrating and global injuries were the most serious, as they could damage the lens, iris, and vitreous, and result in retinal or choroidal detachment. With retinal involvement, an additional 0.2% of patients developed sympathetic ophthalmia [3]. Present treatments of ocular trauma included antibiotics, steroids, and surgical repair [3] [4] [5]. While there were many clinical examples of ocular trauma, the histopathology of retinal responses was not properly documented, and research on animal models was scanty.

While there have been ample studies to justify the use of antibiotics in traumatic eye injury, the effects of retinal lesions with the treatment of traditional medicine were largely unknown. Here, we selected a composite formula of neuroprotection and antiinflammation agents which has been in use for 200 years till this day, its name being Angong Niuhuang pill (Angong). In this composite formula, at least half of the ingredients (herbal or animal components) had neuroprotective and antithrombic activities [6] [7] [8]. Components of three anti-inflammatory herbs in the formula have been classified as ocular protective agents and they were extracts from *Gardenia jasminoides*, *Coptis chinensis* and *Scutellaria baicalensis* [9] [10] [11] [12]. These herb components were reviewed in the Discussion part and the main components of Angong and their effects were reported in a comparative review from our group [13]. In this study, the retinae were chosen for observation and the eyes of the goldfish were used as a model as they have large pigmented eyes and with retinae containing rods and cones. In some aspects, they resemble the eyes of mammals except in lens accommodation and the presence of cartilage in the sclera. Goldfish were also inexpensive for the budget of a small laboratory to conduct research. The objective of this study is to use the eyes of goldfish as a model to demonstrate the effects of

penetration injury and to test the efficacy of antibiotics versus traditional Angong Niu Huang pill treatment.

2. Materials and Methods

Animal experiments were approved by Research Ethics Review Panel for Animal Experiments of the institute. Twelve goldfish (*Carassius auratus*) were used per time in the experiment. All fish were punctured unilaterally on the right eye with an 18-gauge sterile needle of 1.2 mm diameter, at 2 mm above the limbus at the upper middle quadrant of the eye, all the way to the retina but avoiding the lens. The procedure was done under MS-222 (Sigma-Aldrich, Missouri, USA) anesthesia. All twelve fish were then randomly divided into three groups and received eyedrop treatments. One group was treated with saline twice a day for seven days as control. Another group was treated with chloramphenicol eye drops (0.3 mg, Seng Thai Company Limited, Thailand) twice a day for seven days, while the remaining group was treated with a similar dose of Angong Niu Huang pill (0.312 mg, obtained from Zhangzhou Pien Tze Huang Pharmaceutical Company Limited, China, with the Chinese NMPA approval number: Z22021253) twice a day for seven days. After each treatment, the fish were laid flat in a thin layer of water on the uninjured side under anesthesia with 100 mg/L ethyl 3-aminobenzoate methanesulfonate (MS-222) and water flushing through the gills to provide oxygen for ten minutes before being returned to the aquarium. After seven days, all fish were sacrificed via decapitation and the upper quadrant of the eyes with the retina was excised. They were fixed in 10% phosphate-buffered formalin, dehydrated in alcohol, cleaned in xylene, embedded in paraffin, and sectioned at 5 μm for histological studies.

The methods of hematoxylin and eosin (H&E) staining for histopathological observation [14], terminal deoxynucleotidyl transferase dUTP nick end labeling (TUNEL) assay (Merck, Darmstadt, Germany) for apoptotic cell detection, immunohistochemistry (IHC) [15] and statistical analysis [14] were described in our previous research reports. Immunohistochemical reactions targeting cleaved caspase-3 for apoptotic cells, proliferating cell nuclear antigen (PCNA) for proliferative cells, catalase and brain derived neurotrophic factor (BDNF) were performed with anti-cleaved caspase-3 (Cell Signaling, Massachusetts, USA), anti-PCNA (Merck, Darmstadt, Germany), anti-catalase (Abcam, Cambridge, UK) and anti-BDNF (Life Technologies, California, USA) antibodies respectively. Positive cells in 750 μm^2 field were quantified. The experiment was replicated twice to with other stocks of goldfish to make sure the results were consistently in the same direction.

3. Results

Histopathological observation in the controlled saline treated group of goldfish after trauma revealed one fish out of four had retina that displayed distortion of the outer nuclear layer (**Figure 1(a)**) or merging of outer nuclear and inner

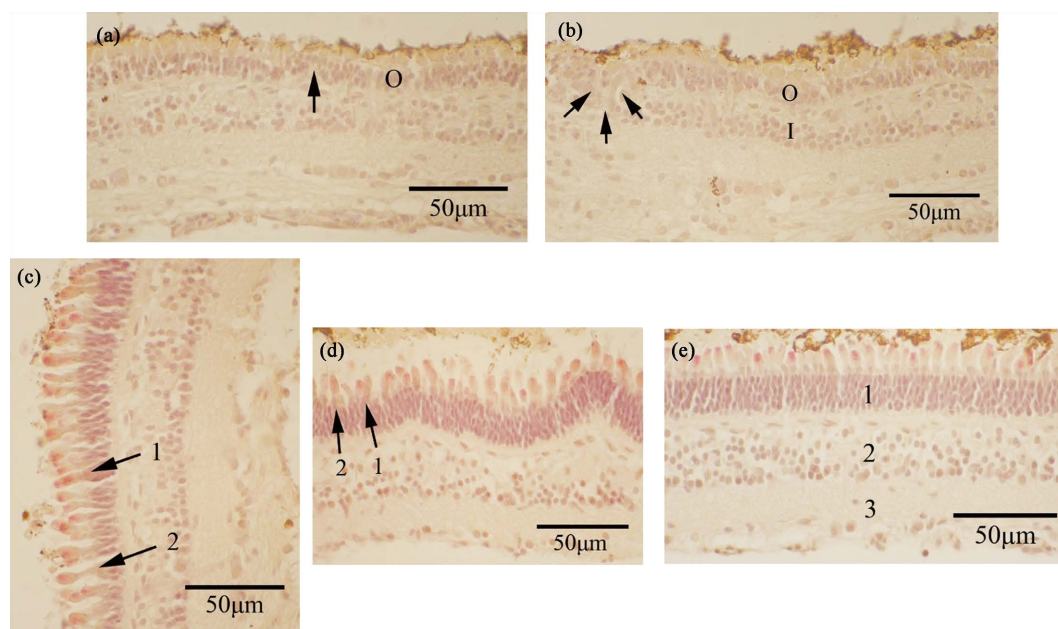


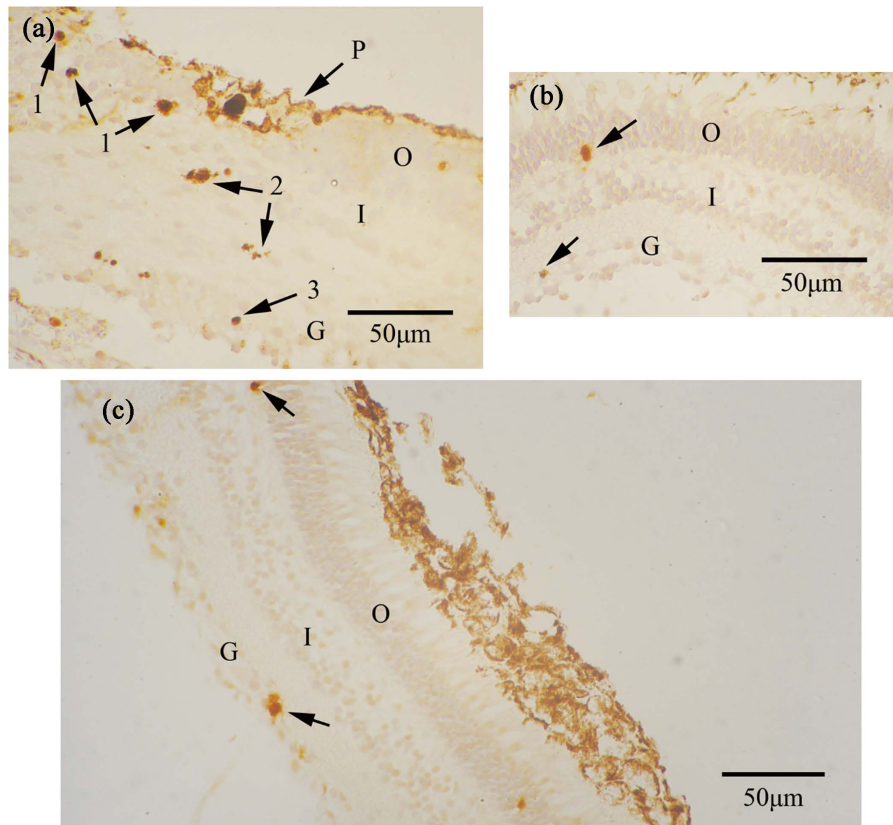
Figure 1. (a) A goldfish retina with saline treatment only after puncture. Note distorting of outer nuclear layer (O) at arrow. 400×. (b) One goldfish retina with saline treatment only after puncture shows the merging of outer nuclear (O) and inner nuclear (I) layers (arrows). 400×. (c) Most retinæ of goldfish with saline treatment after puncture displayed normal visual cells. 1 shows a cone cell and 2 shows a rod cell. 400×. (d) Goldfish with chloramphenicol treatment after puncture. Retina is normal, with 1 is rod cell and 2 is cone cell. 400×. (e) The retina of goldfish treated with Angong after puncture. The retina looks normal. 1 denotes the outer nuclear layer, 2 denotes the inner nuclear layer, and 3 denotes the ganglion cell layer. 400×.

nuclear layers (**Figure 1(b)**), while most of the goldfish retinæ of the same saline treated group had normal looking retinæ with distinct cone and rod visual cells (**Figure 1(c)**). Likewise, the retina of the chloramphenicol treated retina and the Angong treated retina were normal in histology (**Figure 1(d)**, **Figure 1(e)**), except in a few instances, the retina might have displayed wrinkling (**Figure 1(d)**).

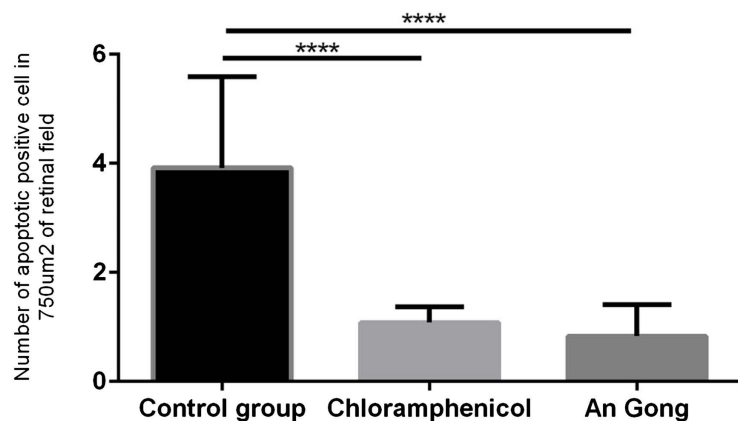
In situ hybridization technique on TUNEL for apoptotic cells revealed many positive TUNEL sites in the outer nuclear, inner nuclear, and a few in the ganglion cell layer of the controlled saline treated traumatic retina (**Figure 2(a)**) while in both the chloramphenicol treated and the Angong treated traumatic retina, much fewer apoptotic cells were seen (**Figure 2(b)**, **Figure 2(c)**) and they were only present in the outer nuclear and ganglion cell layer, with none in the inner nuclear layer (**Figure 2(b)**, **Figure 2(c)**). A semi-quantitative analysis was depicted in **Figure 2(d)** and **Figure 2(e)**. In immunohistochemistry, many cleaved caspase-3 positive cells were observed in the inner nuclear and ganglion layer of saline treated traumatic retina (**Figure 3(a)**) and only few positive cells were found in Angong treated traumatic retina (**Figure 3(b)**).

PCNA immunohistochemistry demonstrated a few positive sites in the outer nuclear layer, the inner nuclear layer, and the ganglion cell layer of the controlled saline treated traumatized retinæ (**Figure 4(a)**). A large increase of PCNA

positive sites was, however, seen in the outer nuclear layer and a little in the inner nuclear and ganglion cell layers of the traumatized retinae treated with chloramphenicol (Figure 4(b)). In the Angong treated traumatized retina, many positive sites were seen in the outer nuclear, inner nuclear, and ganglion cell layers. In particular, the increase in the inner nuclear layer was prominent with some horizontal cells also positive in the Angong treated retinae (Figure 4(c)). The distribution of PCNA positive cells in these retinae was depicted in Figures Figure 4(d) and Figure 4(e). On the other hand, catalase immunoreaction was demonstrated in the inner part of the inner nuclear layer and the ganglion cell



(d) Apoptotic positive cells among treated groups in the outer nuclear layer in each retinal field (750µm²). Three retinal fields for each fish and four fishes for each group.



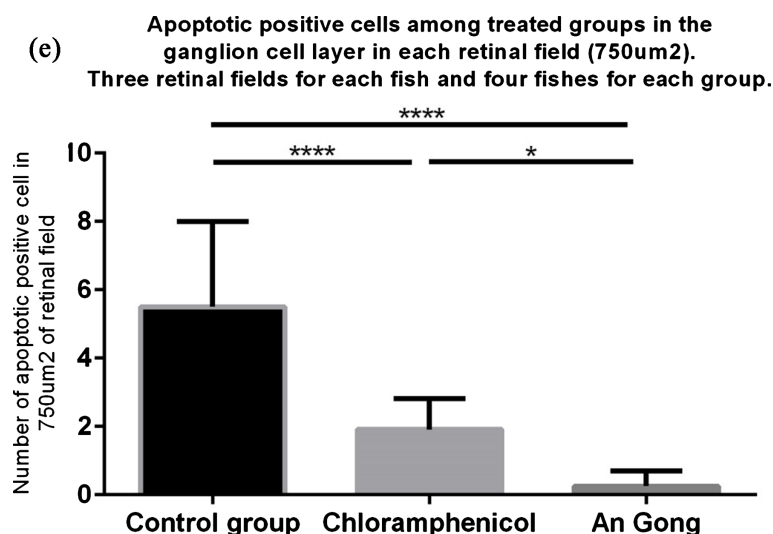


Figure 2. (a) Goldfish retina in punctured eye with only saline treatment. Many TUNEL apoptotic cells were found (1) in outer nuclear layer (O) and (2) in inner nuclear layer (I) and (3) in ganglion cell layer (G). P indicates pigment cells. 400 \times . (b) Goldfish retina of punctured eye treated with chloramphenicol. Note the very few apoptotic TUNEL cells in the outer nuclear layer (O) and ganglion cell layer (G), and nil in the inner nuclear layer (I). 400 \times . (c) Retina treated by Angong after penetration with very few apoptotic cells (arrows), occasionally in the outer nuclear (O) or the ganglion cell layer (G). I denotes the inner nuclear layer. 400 \times . (d) and (e) Positive apoptotic cells were found among all treated groups, *i.e.* three fields for each retina and four fish for each group. The retinal field size is 750 μm^2 . Inner nuclear layer positivity was only found in the control group and was not listed. Significant difference ($p < 0.05$) between control, chloramphenicol, and the Angong group in the ganglion cell layer and significant difference between control and chloramphenicol or the Angong group in the outer nuclear layer. *represents $p < 0.05$. ****represents $p < 0.0001$.

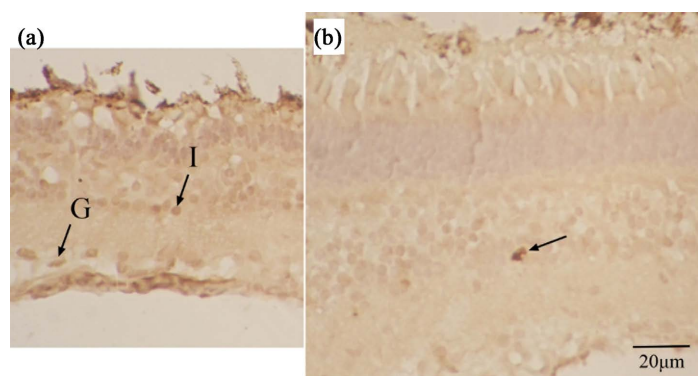
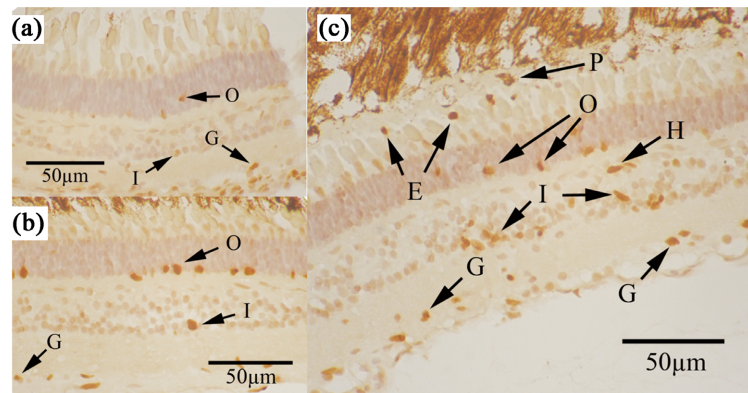
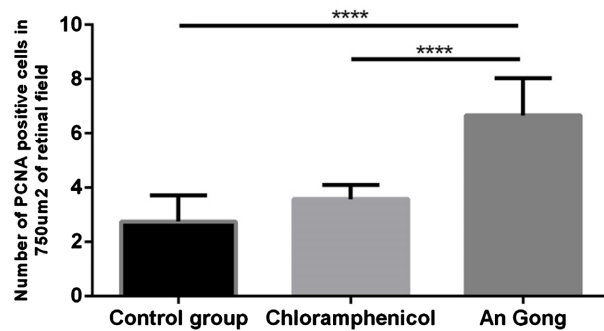


Figure 3. (a) Many cleaved caspase-3 positive cells in the inner nuclear (I) and ganglion cell (G) layers of the control treated retina. 400 \times . (b) An occasional cleaved caspase-3 positive cell in the Angong treated retina. 400 \times .

layer (**Figure 5(a)**) with marginal activity at the base of the outer nuclear layer of the controlled saline treated traumatized retina. In the chloramphenicol treated traumatized retina, some catalase activities were found in the outer nuclear layer with a few sites in the inner nuclear and ganglion cell layer (**Figure 5(b)**). In the Angong treated traumatized retina, no specific positive catalase sites were



(d) Number of PCNA positive cells in the outer nuclear layer in each retinal field (750µm²). Three retinal fields for each fish and four fishes for each group.



(e) Number of PCNA positive cells in the inner nuclear layer plus ganglion cell layer in each retina field (750µm²). Three retinal fields for each fish and four fishes for each group.

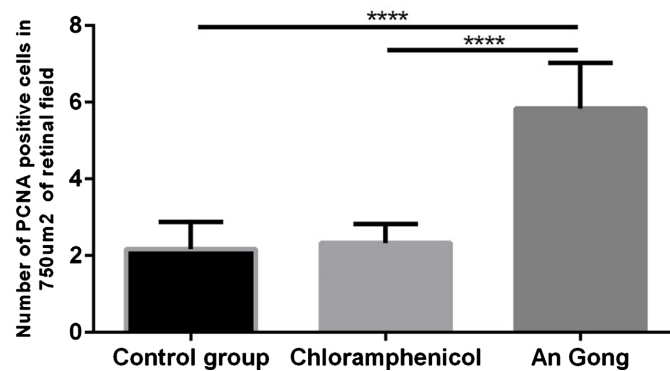


Figure 4. (a) Retina of saline treated goldfish shows only a few positive PCNA cells in the outer nuclear (O), inner nuclear (I) and ganglion cell (G) layers. 400×. (b) Retina of goldfish treated with chloramphenicol with positive PCNA reaction. Note more positive PCNA cells in the outer nuclear layer (O), very few in the inner nuclear layer (I), and a few in the ganglion cell layer (G). 400×. (c) Retina of goldfish treated with Angong. Note a few PCNA cells in the outer nuclear layer (O) but more PCNA cells in the inner nuclear layer (I) and ganglion cell layer (G). Some proliferative cells (P) were also seen in the pigment cell layer and in between pigment cell and visual cells, which might be extruded nuclei (E) from the retinae. H was a positive PCNA horizontal cell. 400×. (d) The number of PCNA positive cells (nuclei) in the outer nuclear layer in each strip of retina of a length of 750 µm² of three experimental groups, four fish in each group, and for each of the three fields was recorded. ****represents $p < 0.0001$. (e) The number of PCNA positive cells in the inner nuclear layer plus ganglion cell layer in each 750 µm² strip of retina. Three retinal fields are recorded for each fish and four fish in each group. ****represents $p < 0.0001$.




Figure 5. (a) Retina of fish treated with saline. Catalase positive cells were seen in the inner nuclear layer (I) and the ganglion cell layer (G). The activity of the outer nuclear layer (O) was marginal and only more at the base of the outer nuclear layer (O) as a background. 400 \times . (b) Retina in fish treated with chloramphenicol. Catalase activity was not significant. Here, catalase is only present in the outer nuclear layer (1) and some inner nuclear (2) and ganglion cells (3). 400 \times . (c) Angong treated retina showing no positive catalase in the retina except some background activity. P indicates pigment epithelium. 400 \times .

observed, other than just general background activity (**Figure 5(c)**).

BDNF immunohistochemistry indicated that in the controlled saline treated traumatized retina, there was no activity in the outer nuclear layer while some activities were observed in the horizontal as well as other cells of the inner nuclear layer and the ganglion cell layer (**Figure 6(a)**). In the chloramphenicol treated traumatized retina, no cells in the outer nuclear layer were positive, but there were cells in the inner nuclear layer that were positive (**Figure 6(b)**). In the Angong treated traumatized retina, the pattern was about the same (**Figure 6(c)**) as that of chloramphenicol. Some horizontal cells were featured along with presumptive amacrine cells (**Figure 6(c)**).

4. Discussion

From our studies, firstly, it was apparent that deep traumatic injury of ocular penetration affected cell death and proliferation, regeneration, and metabolism of the retina, in spite of the few obvious lesions in histopathology. Secondly, the goldfish, as a model of the lower vertebrate, still had an ability to regenerate or repair, and it was evident from the PCNA reactions and BDNF positivity in the traumatized retina of the control with only saline treatment. Moreover, it has been documented that retinal regeneration in fish was possible and was related to the progenitor of Muller cells activated by a single Atoh 7 genes [16]. PCNA positive cells were present in the retinae of saline treated, antibiotic treated and Angong treated groups, Angong treated groups in particular had increased PCNA cells in the inner nuclear layer and the ganglion cell layer, indicating an increased

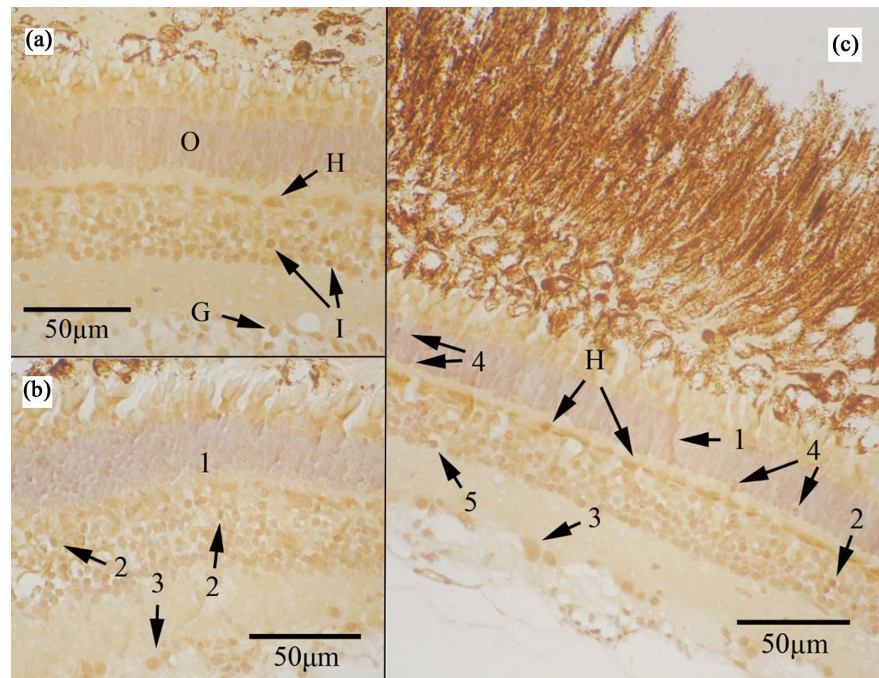


Figure 6. (a) Retina treated with saline shows positive BDNF in the horizontal cell (H), inner nuclear (I) and ganglion cells (G) layers. O denotes the outer nuclear layer. The outer nuclear layer had no positive sites. 400×. (b) Chloramphenicol treated retina with no BDNF positive sites in the outer nuclear layer (1) but some positive inner nuclear cells (2) and ganglion cells (3). 400×. (c) The retina of goldfish treated with Angong shows BDNF positive ascending process to the outer limiting membrane (1) and positive cells in the inner nuclear layer (2). 3 indicates positive ganglion cells. 4 indicates positive cells in the outer nuclear layer. 5 denotes other inner nuclear cells, including horizontal cells (H) and possibly amacrine cells (5). 400×.

proliferation including horizontal, bipolar, Muller and amacrine cells. The Angong treated retina had lots of proliferative PCNA cells, perhaps relating to the presence of neurotrophic factors and neuroprotective agents, e.g. BDNF in the Angong formula [7]. The PCNA positive cells in the outer nuclear layer of the goldfish retina are interesting as well, denoting a proliferation of visual cells after trauma to the retina.

It has also been assumed by some researchers that eyedrop application on the fish after global injury was useless as the fish was put back into water after eye drops. To alleviate this concern, the fish after eye application of saline, chloramphenicol, or Angong were laid flat for ten minutes on the side of the non-injured eye while irrigated with fresh water through the gills after eye drop application (see method). This method ensured that eye drops of chloramphenicol or Angong got into the eye before returning the fish to the water.

Thirdly, both treatments with chloramphenicol and the herbal Angong complex exerted advantages on the traumatized retina over saline treatment in having fewer apoptotic cells (TUNEL and cleaved caspase-3 positive cells), less intense catalase reactions, upregulation of proliferation and more BDNF production.

There are antimicrobial effects of chloramphenicol and the Angong Niuhuang

pill. Chloramphenicol is a known synthetic antibiotic for the eye, while the Angong Niuhuang pill contains three very potent plant extracts with known antimicrobial chemicals. These plants are *Gardenia jasminoides*, *Coptis chinensis* and *Scutellaria copia*. In *Gardenia jasminoides*, geniposides are antimicrobial, anti-inflammatory, and antioxiding agents. On the other hand, Genifrin is antithrombotic and Crocetin is antiapoptotic [17] [18]. In the plant *Coptis chinensis*, the major chemical is berberine, which is antimicrobial, antithrombotic, antiarrhythmic, and neuroprotective [9]. For *Scutellaria baicalensis*, the main chemical is Baicalin which is antimicrobial [19]. The chemical constituents above were documented to affect the blood brain barrier of experimental animals [6] [8].

It is important to note the apoptotic events in the outer nuclear layer of the retina after penetrating injury in our fish model. As the primate has no known regeneration, it would be worrying if the same apoptotic events occur in the outer nuclear layer human without proliferation

Catalase is an enzyme documented for the downregulation of accumulation of cellular hydrogen peroxide and nitric oxide, which are products of oxidation stress from diseases or degeneration [20]. Catalase was found present in fish including *Carassius auratus*, and stress increased catalase after 24 hours in all organs of the fish. Catalase is classical enzyme acting against hydrogen peroxide by converting it to H₂O and oxygen. Accumulation of hydrogen peroxide would lead to increases of catalase expression and accumulation [21]. Our patterns of catalase accumulation showed that in the traumatized fish with saline treatment only, hydrogen peroxide reflected by catalase localization remained strong in the retinae seven days after the lesion. Angong, the retinae of those who received antibiotic and Angong treatments were in better condition. For example, in the Angong treated retinae, no significant catalase activity was seen.

BDNF is a neurotrophin related to the survival and development of neurons and subsequent plasticity [22] [23] [24]. It is synthesized in the axons and dendrites of neurons [25]. In this work, BDNF was observed 7 days after the lesion in the retina, particularly in those groups treated by chloramphenicol and the Angong Chinese herbal complex. In fact, all groups displayed similar patterns of BDNF, indicating that BDNF was present in all traumatic retinae, although in the chloramphenicol and the Angong treated retinae, cells in the outer nuclear layer with positive BDNF cell bodies were observed, pointing to a facilitation of regenerative and repairing ability in the cells of the rods and cones. It is also tempting to postulate that the herbal complex Angong might have certain components that facilitate the production of BDNF. This, however, needs further studies. The Muller cells had their cell bodies located in the inner nuclear layer and provided cytoarchitecture as well as metabolic support to the retina [26]. Seki *et al.* (2005) reported BDNF observed in cultured Muller cells of the rodent [27]. However, in this experiment, not only Muller cells in all groups had BDNF, other cells including horizontal cells and likely other cells in the inner nuclear layer, also had strong BDNF reactions, inclusive of some ganglion cells in gan-

glion cell layer as well. Although Lust *et al.* (2016) reported retinal regeneration could occur from a single gene in Muller progenitor, this work pointed out that many factors were actually activated after global eye penetration induced regeneration [28].

Several other points need to be kept in mind regarding this model and experiment. Firstly, the goldfish retina was pigmented, and retinal detachment was not as easy to happen as in albino rodents. Secondly, this study focused on the recovery period after a week and did not target the initial days immediately after injury. The purpose of this design is to align with the human treatment protocol of seven days. Furthermore, it appears that, based on this experiment, traditional formulas like Angong Niuhuang pill may bear potential in treating eye injury as an eye application, especially in rural areas where antibiotics are not readily available. Having said that, we must acknowledge that there are many types of eye injury and penetration and that this study is but one of them.

5. Conclusion

In this research, some treatment responses of chloramphenicol and Angong on ocular trauma were demonstrated with the goldfish eye penetrating injury model. Treatments with chloramphenicol and the Angong exerted advantages on the traumatized retina over saline treatment in having fewer apoptotic cells, less intense catalase reactions, upregulation of proliferation, and more BDNF production. These pointed out the possible pharmaceutical potential of Angong Niuhuang pill.

Acknowledgements

The authors wish to dedicate this paper to the late Dr. Wai Ying Li, Winnie, for her advice on this work.

Funding

This research was funded by a grant from the Natural Science Foundation of Fujian Province (2016J05210, China).

Conflicts of Interest

The authors declare no conflicts of interest regarding the publication of this paper.

References

- [1] Xia, T., Chen, T.Y., Uppuluri, A., Zarbin, M.A. and Bhagat, N. (2020) Long-Term Outcome of Open Globe Injuries: A 3-Year Follow-Up. *Archives of Clinical and Experimental*, **2**, 44-51. <https://doi.org/10.46439/ophthalmology.2.012>
- [2] Shukla, B., Agrawal, R., Shukla, D. and Seen, S. (2017) Systematic Analysis of Ocular Trauma by a New Proposed Ocular Trauma Classification. *Indian Journal of Ophthalmology*, **65**, 719-722. https://doi.org/10.4103/ijo.IJO_241_17
- [3] Li, X., Zarbin, M.A. and Bhagat, N. (2015) Pediatric Open Globe Injury: A Review of the Literature. *Journal of Emergencies, Trauma, and Shock*, **8**, 216-223.

- <https://doi.org/10.4103/0974-2700.166663>
- [4] Ervin-Mulvey, L.D., Nelson, L.B. and Freeley, D.A. (1983) Pediatric Eye Trauma. *Pediatric Clinics of North America*, **30**, 1167-1183. [https://doi.org/10.1016/S0031-3955\(16\)34509-6](https://doi.org/10.1016/S0031-3955(16)34509-6)
- [5] Janda, A.M. (1991) Ocular Trauma: Triage and Treatment. *Postgraduate Medicine*, **90**, 51-60. <https://doi.org/10.1080/00325481.1991.11701122>
- [6] Guo, Y., Yan, S., Xu, L., Zhu, G., Yu, X. and Tong, X. (2014) Use of Angong Niuhuang in Treating Central Nervous System Diseases and Related Research. *Evidence-Based Complementary and Alternative Medicine*, **2014**, Article ID: 346918. <https://doi.org/10.1155/2014/346918>
- [7] Zhang, D.-S., Liu, Y.-L., Zhu, D.-Q., Huang, X.-J. and Luo, C.-H. (2015) Point Application with Angong Niuhuang Sticker Protects Hippocampal and Cortical Neurons in Rats with Cerebral Ischemia. *Neural Regeneration Research*, **10**, 286-291. <https://doi.org/10.4103/1673-5374.152384>
- [8] Tsoi, B., Chen, X., Gao, C., Wang, S., Yuen, S.C., Yang, D. and Shen, J. (2019) Neuroprotective Effects and Hepatorenal Toxicity of Angong Niuhuang Wan Against Ischemia-Reperfusion Brain Injury in Rats. *Frontiers in Pharmacology*, **10**, Article No. 593. <https://doi.org/10.3389/fphar.2019.00593>
- [9] Latif, A., Razique, A., Asadullah, R.S. and Zuberi, R. (2008) Phytochemical and Physico-Chemical Study of *Coptis teeta* Wall.: An Effective Drug of Choice in Ocular Ailments. *European Journal of Integrative Medicine*, **1**, 22-23. <https://doi.org/10.1016/j.eujim.2008.08.128>
- [10] Chen, J., Tchiveleket, G.M., Zhou, X., Tang, W., Liu, F., Liu, M., Zhao, C., Shu, X. and Zeng, Z. (2021) Anti-Inflammatory Activities of *Gardenia jasminoides* Extracts in Retinal Pigment Epithelial Cells and Zebrafish Embryos. *Experimental and Therapeutic Medicine*, **22**, Article No. 700. <https://doi.org/10.3892/etm.2021.10132>
- [11] Choi, Y.Y., Kim, M.H., Cho, I.-H., Kim, J.H., Hong, J., Lee, T.H. and Yang, W.M. (2013) Inhibitory Effect of *Coptis chinensis* on Inflammation in LPS-Induced Endotoxemia. *Journal of Ethnopharmacology*, **149**, 506-512. <https://doi.org/10.1016/j.jep.2013.07.008>
- [12] Kim, E.H., Shim, B., Kang, S., Jeong, G., Lee, J.-S., Yu, Y.-B. and Chun, M. (2009) Anti-Inflammatory Effects of *Scutellaria baicalensis* Extract via Suppression of Immune Modulators and MAP Kinase Signaling Molecules. *Journal of Ethnopharmacology*, **126**, 320-331. <https://doi.org/10.1016/j.jep.2009.08.027>
- [13] Liu, C., Chen, Z., Wu, S.L., Chow, T.C., Cheng, R.S., Lee, J.T. and Yew, D.T. (2022) Comparative Review on Effects of Pien Tze Huang and AnGong NiuHuang Pill and Their Potential on Treatment of Central Nervous System Diseases. *Mini Reviews in Medicinal Chemistry*. <https://doi.org/10.2174/1389557522666220318111730>
- [14] Chen, Z., Chow, T.C., Wang, S., Leung, G.C., Wu, S.L. and Yew, D.T. (2021) Reaction of the Liver upon Long-Term Treatment of Fluoxetine and Atorvastatin Compared with Alcohol in a Mouse Model. *Journal of Toxicology*, **2021**, Article ID: 9974969. <https://doi.org/10.1155/2021/9974969>
- [15] Lam, W., Wang, C., Tsui, T., Wai, M., Tang, H., Wong, Y., Lam, L., Hui, L. and Yew, D. (2012) Extract of White Button Mushroom Affects Skin Healing and Angiogenesis. *Microscopy Research and Technique*, **75**, 1334-1340. <https://doi.org/10.1002/jemt.22071>
- [16] Miesfeld, J.B., Ghiasvand, N.M., Marsh-Armstrong, B., Marsh-Armstrong, N., Miller, E.B., Zhang, P., Manna, S.K., Zawadzki, R.J., Brown, N.L. and Glaser, T. (2020) The Atoh7 Remote Enhancer Provides Transcriptional Robustness during Retinal

- Ganglion Cell Development. *Proceedings of the National Academy of Sciences*, **117**, 21690-21700. <https://doi.org/10.1073/pnas.2006888117>
- [17] Suzuki, Y., Kondo, K., Ikeda, Y. and Umemura, K. (2001) Antithrombotic Effect of Geniposide and Genipin in the Mouse Thrombosis Model. *Planta Medica*, **67**, 807-810. <https://doi.org/10.1055/s-2001-18842>
- [18] Yoshino, Y., Ishisaka, M., Umigai, N., Shimazawa, M., Tsuruma, K. and Hara, H. (2014) Crocetin Prevents Amyloid β_{1-42} -Induced Cell Death in Murine Hippocampal Cells. *Pharmacology & Pharmacy*, **5**, 37-42.
- [19] Peng, L.-Y., Yuan, M., Wu, Z.-M., Song, K., Zhang, C.-L., An, Q., Xia, F., Yu, J.-L., Yi, P.-F. and Fu, B.-D. (2019) Anti-Bacterial Activity of Baicalin against APEC through Inhibition of Quorum Sensing and Inflammatory Responses. *Scientific Reports*, **9**, Article No. 4063. <https://doi.org/10.1038/s41598-019-40684-6>
- [20] Percy, M.E. (1984) Catalase: An Old Enzyme with a New Role? *Canadian Journal of Biochemistry and Cell Biology*, **62**, 1006-1014. <https://doi.org/10.1139/o84-129>
- [21] Röhrdanz, E. and Kahl, R. (1998) Alterations of Antioxidant Enzyme Expression in Response to Hydrogen Peroxide. *Free Radical Biology and Medicine*, **24**, 27-38. [https://doi.org/10.1016/S0891-5849\(97\)00159-7](https://doi.org/10.1016/S0891-5849(97)00159-7)
- [22] Huang, E.J. and Reichardt, L.F. (2001) Neurotrophins: Roles in Neuronal Development and Function. *Annual Review of Neuroscience*, **24**, 677-736. <https://doi.org/10.1146/annurev.neuro.24.1.677>
- [23] Volosin, M., Song, W., Almeida, R.D., Kaplan, D.R., Hempstead, B.L. and Friedman, W.J. (2006) Interaction of Survival and Death Signaling in Basal Forebrain Neurons: Roles of Neurotrophins and Proneurotrophins. *Journal of Neuroscience*, **26**, 7756-7766. <https://doi.org/10.1523/JNEUROSCI.1560-06.2006>
- [24] Tyler, W.J. and Pozzo-Miller, L. (2003) Miniature Synaptic Transmission and BDNF Modulate Dendritic Spine Growth and Form in rat CA1 Neurons. *The Journal of Physiology*, **553**, 497-509. <https://doi.org/10.1113/jphysiol.2003.052639>
- [25] Lessmann, V., Gottmann, K. and Malsangio, M. (2003) Neurotrophin Secretion: Current Facts and Future Prospects. *Progress in Neurobiology*, **69**, 341-374. [https://doi.org/10.1016/S0301-0082\(03\)00019-4](https://doi.org/10.1016/S0301-0082(03)00019-4)
- [26] Newman, E. and Reichenbach, A. (1996) The Müller Cell: A Functional Element of the Retina. *Trends in Neurosciences*, **19**, 307-312. [https://doi.org/10.1016/0166-2236\(96\)10040-0](https://doi.org/10.1016/0166-2236(96)10040-0)
- [27] Seki, M., Tanaka, T., Sakai, Y., Fukuchi, T., Abe, H., Nawa, H. and Takei, N. (2005) Müller Cells as a Source of Brain-Derived Neurotrophic Factor in the Retina: Norepinephrine Upregulates Brain-Derived Neurotrophic Factor Levels in Cultured Rat Müller Cells. *Neurochemical Research*, **30**, 1163-1170. <https://doi.org/10.1007/s11064-005-7936-7>
- [28] Lust, K., Sinn, R., Pérez Saturnino, A., Centanin, L. and Wittbrodt, J. (2016) *De Novo* Neurogenesis by Targeted Expression of *atoh7* to Müller Glia Cells. *Development*, **143**, 1874-1883. <https://doi.org/10.1242/dev.135905>