



Two Port Laparoscopic Cholecystectomy with a Technical Modification of Using Port Closure Needle (The Chalkoo Modification)

**Mushtaq Chalkoo^{1*}, Zahid Mohd Rather¹, Awhad Mueed Yousuf¹,
Syed Shakeeb Arsalan¹, Ferkhand Mohiuddin¹, Aabid Rasool Bhat¹
and Imtiyaz Ahmad Ganie¹**

¹Government Medical College, Srinagar, India.

Authors' contributions

This work was carried out in collaboration between all authors. All authors read and approved the final manuscript.

Article Information

DOI: 10.9734/JAMMR/2018/45376

Editor(s):

(1) Dr. Dean Markic, Assistant Professor, Department of Urology, University Hospital Rijeka, Croatia.

Reviewers:

(1) Nishith M. Paul Ekka, Rajendra Institute of Medical Sciences, India.

(2) Einar Arnbjörnsson, Lund University, Sweden.

Complete Peer review History: <http://www.sciencedomain.org/review-history/27537>

Original Research Article

Received 13 September 2018

Accepted 24 November 2018

Published 01 December 2018

ABSTRACT

Background: Laparoscopy has revolutionised the gall bladder surgery since inception. There have been more than 30 different ways of performing Laparoscopic cholecystectomy mentioned in the literature. The standard 4 port Laparoscopic cholecystectomy has been modified to 3 port, 2 port, single port, SILS, NOTES cholecystectomy. Two port Laparoscopic cholecystectomy has also been modified in many ways using sutures for the traction of fundus and the infundibulum (puppet technique) and using alligator forceps. We became interested to modify two port lap chole by using port closure needle as a rescue instrument.

Objective: To assess the technical ease, safety and feasibility of using a new instrument (port closure needle) in performing two port laparoscopic cholecystectomy.

Materials and Methods: To assess the safety and technical feasibility of 2 port laparoscopic cholecystectomy using port closure needle as a rescue instrument. We selected a group of 50 patients for a prospective study at Govt. Medical College Srinagar, Kashmir India between January 2016 to January 2018. Our modification of 2 port lap chole resulted in no scar for the port closure

*Corresponding author: E-mail: mushtaq_chalkoo@rediffmail.com;

needle and avoided the time consuming puppet sutures for traction of fundus and infundibulum. The cases were performed by a single surgeon in the unit. The selection criteria for laparoscopic cholecystectomy with 2 port taking assistance with port closure needle were done purely on clinical and Sonographic findings.

Results: The study was performed with a sample size of 50 patients selected purely on radiological findings. Two port laparoscopic cholecystectomy with assistance from port closure needle, offering the benefit of availability of left hand at the operative site was performed in a span of two year. 28 cases were females and 22 cases were males. The age range was between 12 to 50 years with a median age of 25 years. The mean body mass index was 30 (range 25-35). Mean operative time was 20 minutes (range 15-35 minutes) and a follow up period ranged from 6 to 9 months. No cases were converted to open though 4 cases required an additional port which was placed in the umbilicus at its 8 o'clock position.

Conclusion: Laparoscopic two port cholecystectomy taking help from port closure needle gives the benefit of left hand being available to the surgeon, yet avoiding a port and its subsequent scar. It is more convenient, rapid technique over 2 port puppet techniques and 2 port alligator technique. We were satisfied with its good results and patients satisfaction. However, a word of caution is that the port closure needle being a sharp and traumatic instrument needs to be handled carefully even by the expert surgeon.

Keywords: Laparoscopy; ports; gall bladder; port closure needle.

1. INTRODUCTION

Ever since the advent of laparoscopy for the management of benign gall bladder disease, there has been a tremendous advancement over the gold standard four port technique. With the period of time, surgeons became interested in modifying the original standard technique of four ports. Consequently, three port technique, two port technique and single port technique were innovated with an idea to reduce the number of ports and there subsequent problems like port related complications and cosmesis [1]. Single incision laparoscopic surgery (SILS) for benign gall bladder disease also invaded domain of management of gall bladder disease, however, in a meta-analysis [2] of 45 studies (2626) patients on single port laparoscopic cholecystectomy, the rate of bile duct injury was significantly higher in single port than in four port laparoscopic cholecystectomy. This could be attributed to the increasing difficulty that crops up with the number of ports getting reduced [3]. The critical view of safety gets jeopardised as the number of ports decrease. On the other hand, the patient awareness is growing day by day and demand for a particular technique is increasing considering its benefits. It is important to understand that patient safety is the crux of any technique used to manage the gall bladder disease. It needs surgical expertise, experience to practice and carry on these modifications, which without doubt are beneficial for our patient community. Every modification over the standard four port technique has its own indications and

need to be respected for the patient safety. Therefore it is agreed that all patients may not fit for a particular modification as any innovation of port placements may not suit every patient. Two port laparoscopic cholecystectomy, so called puppet technique has its own advocates, however there is a question of putting the suture through the gall bladder and transgressing the parities [4,5,6]. It also is time consuming and with a disadvantage of left hand of surgeon not being available to the operative site. The objective behind our study was to evaluate and assess the safety, technical ease and feasibility of using a new instrument (Port closure needle) in performing two port laparoscopic cholecystectomy. Our technique of two port laparoscopic cholecystectomy with the aid of port closure needle makes the left hand available to the operative site which is of paramount importance. It also avoids time consuming puppet sutures taken through the infected bile and piercing the abdominal wall. Two port technique with assistance from port closure needle should be restricted to indicated cases by expert surgeon.

2. MATERIALS AND METHODS

The study of two port laparoscopic cholecystectomy with the aid of port closure needle was performed in the department of surgery, Govt. Medical College Srinagar between January 2016 to January 2018. Informed consent was obtained from the patients after explaining the procedure in an informal way and ethical

clearance was granted by our College Ethical Committee. We selected 50 patients from our outpatient department with ultrasound proved cholelithiasis. The patients selected for the study were asymptomatic without any clinical evidence of cholecystitis and choledocholithiasis. The procedures were carried out by a single consultant surgeon with an experience of more than 1000 laparoscopic cholecystectomies. On admission patients were evaluated with a detailed history and routine investigations were performed in all patients. All patients had their blood typed and cross matched. Pre anesthetic checkup was done and routine pre operative antibiotic was given in all patients.

3. OPERATIVE TECHNIQUE

The position of the patient is same as in standard four port laparoscopic cholecystectomy. Our technique makes two ports; 10 mm optical port is made in the umbilicus after establishing pneumoperitoneum by veress needle. Another 10 mm epigastric port is made at chalkoo's point [7]. At this stage, we introduce the maryland forcep and survey the anatomy of biliary tract. After ensuring the feasibility of the case being fit for two port technique, we precede further to carry the procedure with the aid of port closure needle. A stab incision with 11mm knife is made exactly at the site of third port. It is 2 mm stab through which 15 cm long and 1 to 2 mm wide port

closure needle is guided with both hands and screwed in to the abdominal cavity carefully, taking care not to injure the liver or adjacent viscera. This technique makes both hands available to the dissection site. The port closure needle is used to hold the Hartmann's pouch and pull to the right and out with a view to expose the calot's triangle. The dissection is done by marylands forcep to expose the cystic artery and cystic duct. We place clips or single hand suture to the duct and artery and dissect out the gall bladder from the liver bed taking aid of port closure needle. Gall bladder with stones is removed through the epigastric port. Haemostasis is achieved and suction irrigation done. Ports are closed and dressing is applied. The patients are made ambulatory on the evening of the same day and liquid orals are given. The patient is discharged in the evening or at the most of morning of first post operative day (Figs. 1 to 5).

4. RESULTS AND ANALYSIS

4.1 Age and Sex

50 patients under went modified two port laparoscopic cholecystectomy. The median age of patients was 25 years and the range was 12 - 50 years. There were 28 females and 22 males in the study.

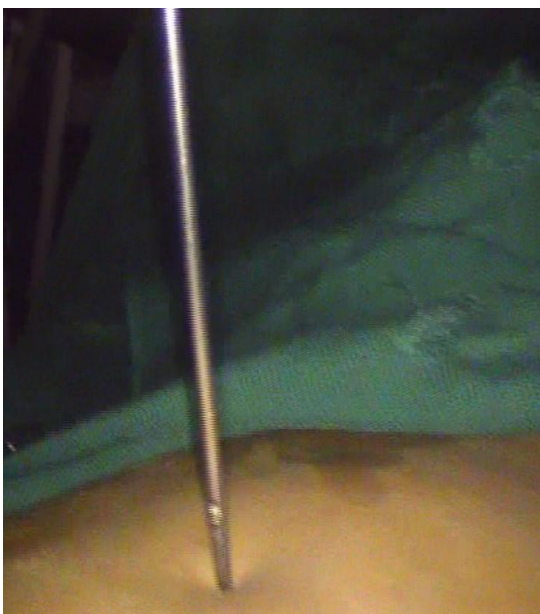

Fig. 1. Port closure needle

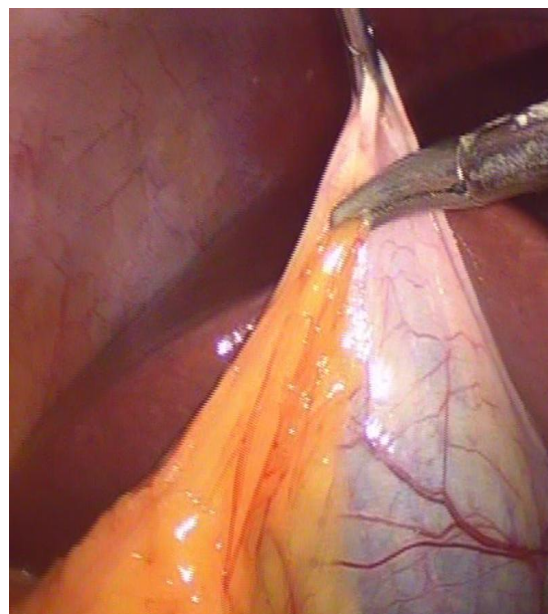

Fig. 2. Port closure needle to retract fundus

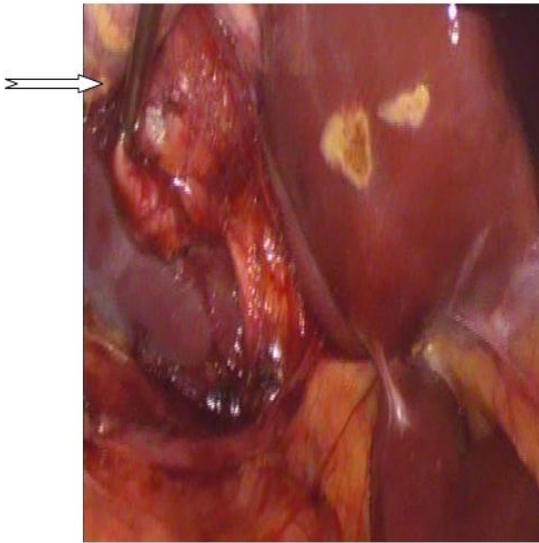


Fig. 3. Holding Hartmann's Pouch to ensured Critical view

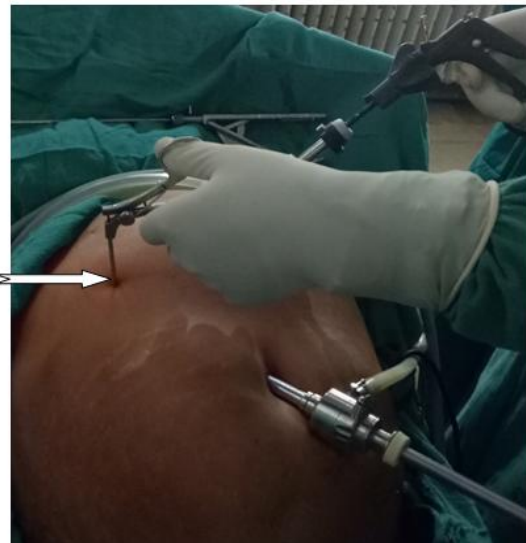

Fig. 4. Port position and port closure needle marked by arrow

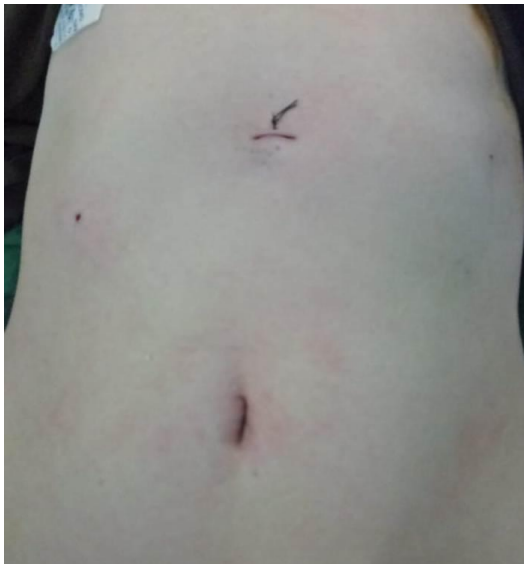

Fig. 5. Post operative scar and

4.2 Body Mass Index (BMI)

Mean body mass index Was 30 (range 25-35).

4.3 Previous Intervention/ Surgeries

None of our patients had a history of previous upper abdominal surgical intervention.

4.4 Pre-operative Details

The operative time, estimated blood loss, requirement of transfusion, intra-operative

complications, use of suction / tube drain, requirement of adding the 3th port and reasons thereof were recorded. The third port was required to be inserted in 4 patients due to technical difficulty of handling them with port closure needle. There were three complications (6%). All complications were minor in the form of diffuse hemorrhagic ooze from liver bed in two patients and bilious ooze in one patient. Both these were coming from the gall bladder bed. The complications were managed intra-operatively by securing the proper haemostasis. There was no major bile duct injury in our study. No patient demanded conversion to open cholecystectomy.

4.5 Post-operative Details

Two of our patients developed post operative complications. One of the patient developed epigastric port site infection. This was managed by antiseptic dressing twice daily with a short course of antibiotics against staphylococcus. Another patient developed fever due to thrombophlebitis which was treated with change of intra venous access site and local heparin cream.

4.6 Hospital Stay

The mean hospital stay was 1.2 days the range being 1-2 days. Most of the patients were discharged home on the evening or morning of first post operative day. The hospital stay got

prolonged up to 2 days in patients who developed the above post operative complications.

4.7 Return to Work

Most of the patients returned to their normal routine work within 1 week of surgery.

4.8 Follow Up

All patients were followed strictly after the surgery. The mean follow up was 6 months (range 9- 12) months. Most of these patients had only one visible scar in the epigastric region at 6 months follow up.

5. DISCUSSION

Man is inquisitive in nature. It is his innate desire to modify his own ideas, proposals and designs in every field of art. The art of surgery is not exempt from this way of life in surgeon's career. Laparoscopy has become now the cherished art of practice of surgery across the globe. Laparoscopic cholecystectomy has become affordable, beneficial and practicable by majority of surgeons. Our new generation of surgeons has taken this art to the newer horizons. Four port laparoscopic cholecystectomy is a standard technique practiced globally even now. However new and newer techniques are born every other day. There has been mushrooming of newer techniques in handling the benign gall bladder stone disease. The commonality and theme behind any innovation and technical modification has always been to reduce the number and size of ports and to alleviate the pain and give the benefit of better cosmesis to the patients [8]. However any technique has its advantages as disadvantages too. Is fourth port really required in laparoscopic cholecystectomy was an idea that became a research question for us to work on and we concluded that it may not be mandatory and one can avoid it in many circumstances wherein three ports are enough to accomplish the job safely [9]. Consequently we became interested in avoiding the third port at its prescribed place in the right hypochondrium and tried a new place of putting it in the concealed area. The study published in this regard was in experience of putting the third port in the umbilical ring at 8 o'clock position on the right side [10]. However it needed a 5 mm port to be made and its subsequent scar though concealed. As we grew with our experience we felt interested in avoiding the third port and

managing the disease process with two ports only. Looking at how the surgeons have performed two port laparoscopic cholecystectomy we came across different techniques and innovations [11]. Important ones to mention are the puppet technique and alligator forcep technique. There are many proponents of this technique as others have many queries against them. We strongly feel that the puppet technique makes the surgeon handicap of left hand not being available to the operative site [12]. It is time consuming and perforates the infected gall bladder. In the current study we tried to modify the two port laparoscopic cholecystectomy with an idea to use the port closure needle as a rescue instrument. This technique avoids a definite 5 mm port and its subsequent scar, yet it has an advantage of making the left hand available to the operative site which is ergonomically of paramount importance for the surgeon to accomplish operative procedure with confidence. It also allows the retraction of liver at any time of surgery to handle any untoward problem to control. Port closure needle does not result any additional pain or scar at the end of the procedure. We observed that only indicated cases can be handled by this technique and whenever any difficulty would arise we would convert to a formal port making and carry the procedure in the interest of the safety of the patient. There is a word of caution that port closure needle is a sharp instrument should be always be kept under the vision of surgeon and handled carefully to avoid injury to liver and gut.

6. CONCLUSION

Our study has taught us that two port laparoscopic cholecystectomy with our modification is feasible, reproducible and easily practicable. It has an advantage of avoiding pain and scar of 5 mm port. It provides practically two hands to handle the operative job. However the port closure needle should be handled carefully and kept in vision all the time.

CONSENT

As per international standard or university standard, patient's written consent has been collected and preserved by the author(s).

ETHICAL APPROVAL

As per international standard or university standard, written approval of Ethics committee

has been collected and preserved by the author(s).

COMPETING INTERESTS

Authors have declared that no competing interests exist.

REFERENCES

1. Leggett PL, Churchman-Winn R, Miller G. Minimizing ports to improve laparoscopic cholecystectomy. *Surg Endosc.* 2000; 14(1):32-6.
2. Joseph M, Phillips MR, Farrell TM, Rupp CC. Single incision laparoscopic cholecystectomy is associated with a higher bile duct injury rate: A review and a word of caution. *Ann. Surg.* 2012;256:1-6.
3. Strasberg SM, Hertl M, Soper NJ. An analysis of the problem of biliary injury during laparoscopic cholecystectomy. *J. Am. Coll. Surg.* 1995;180:101-125.
4. Endo S, Souda S, Nezu R, Yoshikawa Y, Hashimoto J, Mori T, et al. A new method of laparoscopic cholecystectomy using three trocars combined with suture retraction of gallbladder. *J Laparoendosc Adv Surg Tech A.* 2001;11:85-8.
5. Ramachandran CS, Arora V. Two-port laparoscopic cholecystectomy: An innovative new method for gallbladder removal. *J Laparoendosc Adv Surg Tech A.* 1998;8:303-8.
6. Bhandarkar D, Mittal G, Shah R, Katara A, Udwadia TE. Single-incision laparoscopic cholecystectomy: How I do it? *J Min Access Surg.* 2011;7:17-23.
7. Chalkoo M, Ahangar S, Baqal FS, et al. A point-specific site for placement of epigastric port in laparoscopic management of gallbladder disease: An observational study. *Surgical Science.* 2013;4:309-312.
8. Leggett PL, Churchman-Winn R, Miller G. Minimizing ports to improve laparoscopic cholecystectomy. *Surg Endosc.* 2000; 14(1):32-6.
9. Chalkoo M, Ahangar S, Durrani AM. Is fourth port really required in laparoscopic cholecystectomy? *Indian J Surg.* 2010; 72(5):373-376.
10. Mushtaq Chalkoo, Shahnawaz Ahangar, Aasim Mushtaq Patloo, et al. A medical school experience with three port laparoscopic cholecystectomy with a new modification in technique. *International Journal of Surgery.* 2013;11:37-40.
11. Gadacz TR, Talamini MA, Lillemoie KD, Yeo CJ. Laparoscopic cholecystectomy. *Surg Clin North Am.* 1990;70(6):1249-62.
12. Ming G. Tian, Pei J. Zhang, Yang Y, Fan J. Shang, Zhan J. Two-port laparoscopic cholecystectomy with modified suture retraction of the fundus: A practical approach. *J Minim Access Surg.* 2013; 9(3):122-125.

© 2018 Chalkoo et al.; This is an Open Access article distributed under the terms of the Creative Commons Attribution License (<http://creativecommons.org/licenses/by/4.0>), which permits unrestricted use, distribution, and reproduction in any medium, provided the original work is properly cited.

Peer-review history:

The peer review history for this paper can be accessed here:
<http://www.sciencedomain.org/review-history/27537>